ISSN 2664-472X
e ISSN 2664-4738

Medical Science of Ukraine

Медична наука України

2020, Vol. 16, № 4

Medical Scitnce of Ukraine. 2020, Vol. 16, №4

ISSN 2664-472X
16
9 772664 472004

ISSN 2664-472X
e ISSN 2664-4738
https://doi.org/10.32345
Medical science of Ukraine
2020, Vol. 16, № 4

Certificate of state registration:
KB № 21521-11421ПР dated 18.08.2015

Periodicity:
published four times a year

Scientific and practical journal in the field: Medicine.
Distributed in Ukraine and abroad

Founder:
Bogomolets National Medical University

Editor in Chief: Zemskov S. V.

Deputy Chairmen of the Editor in Chief: Kanyura O. A.

Members of the editorial board:

Omelchuk S. T., Ziablitsev S. V., Gruzeva O. V. (Sweden), Grando S. O. (USA), Babel N. (Germany), Kulchytsky V. A. (Belarus), Nizhenkivska I. V., Khaytovych M. V., Iaremenko O. B., Natrus L. V., Dyndar O. A., Zhaboedov D. G., Zakharash U. M., Dzhus M. B., Panova T. I., Zhegulovych Z. E.,Ventskivskiy B. M., Mykhailachenko B. V., Ushko Ia. A., Nishkumay O. I., Sova S. G., Netyazhenko N. V., Vygovska O. V., Guryanov V. G., Chaly K. O., Kulbashna Y. A.

The journal «Medical Science of Ukraine» is included in the list of scientific professional editions of Ukraine (category "B"), which are recommended for publication of dissertation materials for obtaining scientific degrees of the doctor of sciences (Sc.D.) and candidate of sciences (Ph.D.).
Branch of science – medical sciences in the following specialties:

221 – Dentistry
222 – Medicine
224 – Technologies of medical diagnostics and treatment
225 – Medical psychology
226 – Pharmacy, industrial pharmacy
227 – Physical therapy, occupational therapy
228 – Pediatrics
229 – Public Health

Order of the Ministry of Education and Science of Ukraine on 26th of November, 2020, No. 1471 (Appendix 3, paragraph 44)

Order of the Ministry of Education and Science of Ukraine on 13th of March, 2017, No. 374

The decision of the State Accreditation Commission of Ukraine on 18th of November, 2009, № n 1-05/5

Address of the editor:
Shevchenko's boulevard, 13, Kyiv, 01601

For correspondence:

01601, Kyiv, Shevchenko's boulevard, 13
Tel/fax (044) 234-69-75; (095) 244-27-26
Web-site: msu-journal.com
E-mail: msu@nmu.ua; msu.nmu34@gmail.com

For the reliability of the information in the publications, the authors of the article bear responsibility. Author's materials do not always reflect the point of view of the editorial staff.
In case of reprinting the reference is required.

Recommended for publication
by the Academic Council of the O.O. Bogomolets National Medical University 22.12.2020, protocol № 7

Signed for print 23.12.2020
Conditional printed sheets 11. Format 60x84 1/8.
Circulation 500 copies.
Published by Publishing House "KIM"
Krzhizhanovskogo Str., 3. Kyiv, 03680, Kyiv
Phone: +38044 221 41 05
Certificate DK № 2888 from 03.07.2007.

ISSN 2664-472X
e ISSN 2664-4738
https://doi.org/10.32345
Медична наука України
2020, Т. 16, № 4

Свідоцтво про державну реєстрацію
КВ № 21521-11421ПР від 18.08.2015

Періодичність видання
1 раз на квартал

Галузь науки: медична
Категорія: Б
Статус видання: розповсюджується в Україні та за кордоном

Засновник
Національний медичний університет імені О.О. Богомольця

Головний редактор: Земсков С. В.

Заступник редактора: Канюра О. А.

Члени редколегії:

Омельчук С. Т., Зябліцев С. В., Грузєва О. В. (Швеція), Грандо С. О. (США), Бабель Н. (Німеччина), Кульчицький В. А. (Білорусь), Ніженківська І. В., Хайтович М. В., Яременко О. Б., Натрус Л. В., Диндар О. А., Жабоєдов Д. Г., Захараш Ю. М., Джус М. Б, Панова Т. І., Жегулович З. Є., Венцківський Б. М., Михайліченко Б. В., Ушко Я. А., Нішкумай О. І., Сова С. Г, Нетяженко Н. В., Виговська О. В, Гур'янов В. Г., Чалий К. О., Кульбашна Я. А.

Журнал «Медична наука України» включено в категорію «Б» – перелік наукових фахових видань України, рекомендованих для публікації дисертаційних матеріалів на здобуття наукових ступенів доктора наук, кандидата наук та доктора філософії у галузі «Медицина», спеціальності:

221 – стоматологія;
222 – медицина;
224 – технології медичної діагностики та лікування;
225 – медична психологія;
226 – фармація, промислова фармація;
227 – фізична терапія, ерготерапія;
228 – педіатрія;
229 – громадське здоров'я.

Наказ Міністерства освіти та науки України від 26.11.2020, № 1471 (Додаток 3, пункт 44).

Наказ Міністерства освіти та науки України від 13.03.2017, № 374

Постанова Президія Вищої Атестаційної Комісії України від 18.11.2009, № n 1-05/5

Адреса редакції:
01601, м. Київ, бульв. Т. Шевченка, 13

Для кореспонденції:

01601, м. Київ, бульв. Т. Шевченка, 13
Тел./факс (044) 234-69-75; моб. (095) 244-27-26 (секретар)
Сайт видання: msu-journal.com
E-mail: msu@nmu.ua; msu.nmu34@gmail.com

За достовірність інформації в публікаціях відповідальність несуть автори статті. Авторські матеріали не завжди віддзеркалюють точку зору редакції.
При передруку посилання обов'язкове.

Рекомендовано до друку
Вченою радою Національного медичного університету імені О.О. Богомольця 22.12.2020, протокол № 7

Підписано до друку 23.12.2020
Ум. друк. арк. 11. Формат 60x84 1/8.
Тираж 500 прим.
Надруковано у ТОВ «Видавництво КІМ»
Україна, 03680, м. Київ, вул. Кржижановського, 3,
Тел. +38044 221 41 05
Свідоцтво ДК № 2888 від 03.07.2007.

Medical Science of Ukraine
Медична наука України

2020, Vol. 16, № 4

Національний медичний університет імені О.О. Богомольця

https://doi.org/10.32345/2664-4738.4.2020

Періодичність видання – 1 раз на квартал

ЗМІСТ

ТЕОРЕТИЧНА МЕДИЦИНА

Huranych S.P., Voronych-Semchenko N.M., Bagrii M.M. Structural changes of the oral mucosa in rats with insulin resistance, iodine deficiency and under conditions of their combination 3

КЛІНІЧНА МЕДИЦИНА

Turchina N.S., Cherenko T.M., Trepet L.N., Rybalko S.L., Starosyla D.B. Incidence of confirmed manifest viral infection in cases of ischemic stroke, depending on the season 8

Rykov S.O., Korobov K.V., Mogilevskyy S.Yu., Ziablitsev D.S. Progression of diabetic non-proliferative retinopathy in type 2 diabetes mellitus: the connection with the blood endothelial monocyte-activating polypeptide-II level 15

Minaiev O.O. Complications in surgical treatment of patients with chronic dacriocystitis 22

Kryzhanivska O.O. Iris changes at patients with temporomandibular joint diseases and urinary system pathology 28

Tongshuwar G.T., Ojetunde A O., Oyegoke A.F., Oyegoke T. Ethno-botanical survey of plants used in a rheumatoid arthritis treatment: a case study of Jos in Nigeria 35

CONTENT

THEORETICAL MEDICINE

Huranych S.P., Voronych-Semchenko N.M., Bagrii M.M. Structural changes of the oral mucosa in rats with insulin resistance, iodine deficiency and under conditions of their combination

CLINICAL MEDICINE

Turchina N.S., Cherenko T.M., Trepet L.N., Rybalko S.L., Starosyla D.B. Incidence of confirmed manifest viral infection in cases of ischemic stroke, depending on the season

Rykov S.O., Korobov K.V., Mogilevskyy S.Yu., Ziablitsev D.S. Progression of diabetic non-proliferative retinopathy in type 2 diabetes mellitus: the connection with the blood endothelial monocyte-activating polypeptide-II level

Minaiev O.O. Complications in surgical treatment of patients with chronic dacriocystitis

Kryzhanivska O.O. Iris changes at patients with temporomandibular joint diseases and urinary system pathology

Tongshuwar G.T., Ojetunde A O., Oyegoke A.F., Oyegoke T. Ethno-botanical survey of plants used in a rheumatoid arthritis treatment: a case study of Jos in Nigeria

ДЛЯ ПРАКТИКУЮЧОГО ЛІКАРЯ

Antsupva V.V., Lastivka I.V., Kolubakin D.V., Ushko Y.A., Nahornyi O.V. Modern views regarding the etiopathogenesis, diagnosis, treatment and prevention of Apert syndrome 46

Babkina O.P., Ushko I.A., Danylchenko S., Tarasyuk V., Vako I. The cases of domestic violence in protracted quarantine caused by COVID-19 51

ОГЛЯДИ

Khaitovych M.V., Turchak D.V. Jilber's syndrome: clinical and pharmacological aspects. Review *58*

FOR PRACTICING DOCTOR

Antsupva V.V., Lastivka I.V., Kolubakin D.V., Ushko Y.A., Nahornyi O.V. Modern views regarding the etiopathogenesis, diagnosis, treatment and prevention of Apert syndrome

Babkina O.P., Ushko I.A., Danylchenko S., Tarasyuk V., Vako I. The cases of domestic violence in protracted quarantine caused by COVID-19

REVIEW

Khaitovych M.V., Turchak D.V. Jilber's syndrome: clinical and pharmacological aspects. Review

DOI: https://doi.org/10.32345/2664-4738.4.2020.01
UDC: 616.31+616-092.9+616.379-008.64+546.1

STRUCTURAL CHANGES OF THE ORAL MUCOSA IN RATS WITH INSULIN RESISTANCE, IODINE DEFICIENCY AND UNDER CONDITIONS OF THEIR COMBINATION

Huranych S.P. (https://orcid.org/0000-0001-5707-0649)
Voronych-Semchenko N.M. (https://orcid.org/0000-0001-9872-6640)
Bagrii M.M. (https://orcid.org/0000-0001-9792-1065)

Ivano-Frankivsk National Medical University, Ivano-Frankivsk, Ukraine
guranichtanja@ukr.net

Relevance. The relationship between endocrinopathies and the condition of the oral cavity is associated with disorders of metabolism, hemodynamics, immunological and neuroregulatory changes. Since the first line of contact with the environment of the oral cavity is the mucous membrane, changes in its properties adversely affect the functional state of other periodontal tissues.

Objective: to examine the structural changes of the oral mucosa in rats with combined endocrinopathy.

Materials and methods. The studies were carried on 120 rats, which were divided into three experimental (animals with iodine deficiency – ID, insulin resistance – IR, IR on the background of ID) and a control groups of animals. Histological examination of oral mucosa, computer morphometry and densitometry of objects were performed.

Results. In rats with ID, the epithelium of the mucous membrane was characterized by the development of acanthosis, expansion of the granular layer, enhanced keratin formation. The development of IR caused hyperplastic changes in the epithelium with the formation of unexpressed cords of acanthosis, epithelial basal hypercellular infiltration, which was confirmed by morphometric data. Under conditions of combined endocrinopathy, more pronounced changes in the histological structure of oral mucosa were observed. In particular, the development of mucosal edema in connective tissue, with predominantly macrophage hypercellularity at the periphery, was noted. Densitometric examination of the samples indicated a decrease in the optical density of connective tissue. At the same time, hyperplastic changes in most layers of the epithelium and pronounced changes in the vascular wall were observed.

Conclusions. Combined endocrinopathy leads to pronounced changes of oral mucosa, which can lead to disruption of the structure of periodontal tissues and the entire tooth-alveolar complex.

Key words: insulin resistance, iodine deficiency, oral mucosa, histological changes.

RELEVANCE

Pathology of endocrine glands is one of the most common non-infectious diseases of the modern world. The combination of several endocrine nosologies is especially dangerous in the prognostic aspect. The relationship between endocrinopathies and the state of oral cavity is quite close and it is associated with the disorders of metabolism, hemodynamics, immunological and neuroregulatory changes [2]. Since the first line of contact with the oral cavity environment is the mucous membrane, the changes of its protective, barrier and sensory properties adversely affect the functional state of other periodontal tissues. In particular, the violation of tolerance to glucose is a trigger for the microcirculatory changes in the oral mucosa, due to the accumulation of end products of glycation, damage of connective tissue proteins, formation of inflammatory cytokines and adipokines [3]. These changes lead to plasma hyperfiltration from the vascular net, hemorrhages, hypoxia, metabolic acidosis, followed by the development of structural changes in oral mucosa [6]. In turn, under conditions of thyroid hormones deficiency, the course of all metabolic processes is slowed down, what is manifested by the deposition of fibronectin and hydrophilic glycosaminoglycans in the tissues in the form of mucinous edema [4, 5].

Objective: to examine the structural changes of oral mucosa in rats with combined endocrinopathy.

MATERIALS AND METHODS

The studies were conducted on 90 female rats weighing 150-180 g, which were divided into three experimental groups (30 animals in each group). The 1st group included rats with iodine deficiency (ID), which was reproduced by keeping animals on a diet with limited iodine intake during two months [8]; to the 2nd - rats with insulin resistance (IR), which was modeled by adding to the drinking water of animals 10 % fructose solution during 8 weeks [7]; to the 3rd - rats with IR on the background of ID. The control group (n=30) included intact animals, which were kept on a standard diet, normal temperature and light regime of the vivarium.

Thyroid status was determined by the content of free triiodothyronine (fT3), thyroxine (fT4), thyroid-stimulating hormone of adenohypophysis (TSH) in the blood serum by enzyme-linked immunosorbent assay. The state of iodine supply of rats was studied by the examination of iodine concentration in the single urine portions, collected by metabolic cages method. The hydrocarbon metabolism was assessed by the level of immunoreactive insulin (IRI) in the blood serum, the content of glycosylated hemoglobin and the concentration of glucose in the blood.

For general and special histological examinations the fragments of the mucous membrane were fixed in a 10 % solution of neutral formalin (Ph-7.0). The fixation time was 24 hours. Formation of serial paraffin sections of oral mucosa with a thickness of 4-6 μm was performed on a sledge microtome. Histological sections of the mucosa were stained with hematoxylin and eosin, alcyan blue according to Sidman and PAS staining (Periodic Acid Schiff Reaction) was made [1]. The studies were performed in a Leica DME optical microscope. In order to objectify the quantitative data, the computer morphometry and densitometry of objects in histological specimens were performed. Digital copies of the image were analyzed by using the computer program Image Tool 3.0 for Windows.

The morphometric analysis of oral mucosa was performed taking into account the following indicators: epithelial thickness; depth and width of acanthosis; thickness of basal, prickle, granular, keratinized layers of epithelium; perimeter and area of the cells nucleus of all epithelium layers; perimeter and area of cells of all epithelial layers; optical density of the ground substance of the connective tissue.

Keeping, feeding and euthanasia of animals were carried out following the generally accepted bioethical standards of humane treatment of experimental animals of international and national regulations for animal experiments: «European Convention for the Protection of Vertebrate Animals for Research and Other Scientific Purposes» (Strasbourg, 1986); «General ethical principles of animal experiments» (Ukraine, 2001); The Law of Ukraine «On protection of animals from cruel treatment» №2447-IV (Ukraine, 2006). Quantitative research results were analyzed using mathematical software package Statistic Soft 7.0. Statistically significant difference was considered at $p<0.05$.

RESULTS AND THEIR DISCUSSION

The changes of thyroid homeostasis were observed in animals with ID compared to control data. It should be noted that the lack of iodine supply led to morphological changes of oral mucosa. Thus, the squamous epithelium, which covered the oral mucosa, was characterized by the development of acanthosis (Fig. 1).

It should be noted that keratohyalin granules were traced in some deeper epithelial cells, which indicated the expansion of the granular layer as a prerequisite for enhanced keratin formation (Fig. 2). Such changes were confirmed by the data of morphometric examination of the stratum corneum, the thickness of which in rats with ID by 20.9 % ($p<0.02$) exceeded the similar indicators of animals in the control group. The lumen of vessels of the microcirculatory net as well as the small arteries and veins, was opened, which was clearly seen in PAS-staining due to the visualization of glycoproteins of the vascular walls.

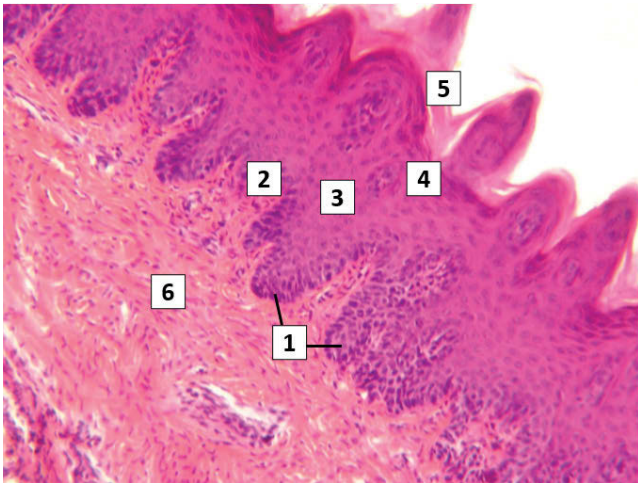

Fig. 1. Epithelium of the oral mucosa under conditions of iodine deficiency Staining: hematoxylin and eosin × 200
1 – acanthosis of the epithelium, 2 – basal layer of epithelium, 3 – prickle layer of epithelium, 4 – granular layer of epithelium, 5 – keratinized layer, 6 – subepithelial connective tissue

Fig. 2. Epithelium of the oral mucosa under conditions of iodine deficiency Staining: hematoxylin and eosin × 200
1 – keratohyalin granules in the cells of prickle layer, 2 – acanthosis of the integumentary epithelium

The development of IR in animals of the 2nd experimental group was confirmed by changes of hydrocarbon metabolism. Violation of tolerance to glucose was accompanied by the structural rearrangement of oral mucosa. Thus, the epithelium thickness is uneven due to hyperplastic changes with the formation of unexpressed cords of acanthosis, caused by epithelial basal hypercellularity, which was confirmed by morphometric data. In particular, the thickness of the basal layer of the epithelium of rats of the 2nd experimental group increased by 53.4 % ($p<0.05$) relative to the correspondent indicators in intact animals. It should be noted that the morphometric parameters of epitheliocytes of most layers of oral mucosa were decreased. In particular, the area of the cells of prickle and granular layers decreased

by 11.3 % ($p<0.05$) and by 20.5 % ($p<0.05$) according to the control values. Similar changes were observed in the cell nuclei. Thus, the perimeter and area of the nuclei of the cells of prickle and granular layers decreased by 11.0-37.0 % ($p<0.05$) relative to similar indexes in intact animals. At the same time, in capillaries and arterioles narrowing of a lumen was noticed. The reason for these changes can be considered the plasma impregnation with loosening of the vessel wall with simultaneous endotheliocyte hyperplasia. The subepithelial basement membrane after the hematoxylin and eosin staining was seen indistinctly due to fusion with connective tissue fibers. Its clearer visualization was observed in areas of less pronounced acanthosis. After PAS-staining the state of a membrane visualized more accurately. In small arteries the tortuous internal elastic membrane with folds, areas of uneven width and depth was accurately traced. After PAS-staining the inner elastic membranes was PAS-positive. In the areas of pronounced tortuosity the increment accumulation of glycoproteins was found (Fig. 3).

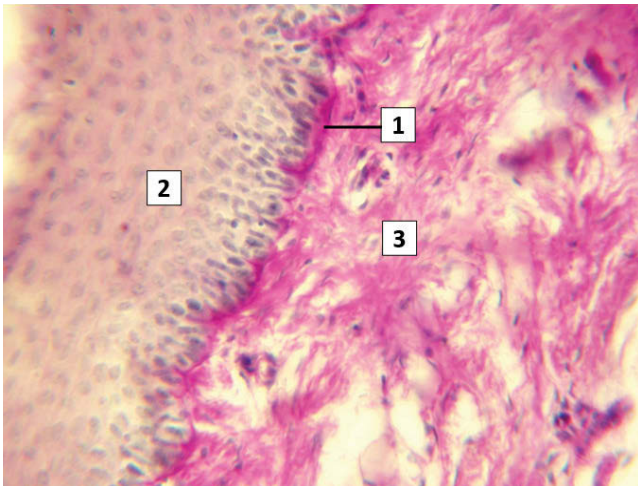

Fig. 3. The oral mucosa under conditions of insulin resistance Staining: PAS × 400
1 – PAS-positive basal membrane, 2 – epithelium, 3 – subepithelial connective tissue with PAS-positive glycoproteins

Under the conditions of IR on the background of ID the more pronounced changes of thyroid status and hydrocarbon metabolism was observed, which was accompanied by the violation of the histological structure of oral mucosa. In particular, the development of mucosal edema in the connective tissue was noticed, which could be traced by staining with hematoxylin and eosin in the form of blue areas, devoid of connective tissue fibers, due to their displacement. Mostly on the periphery of the edema areas a slight hypercellularity was found, mainly due to macrophages (Fig. 4).

In animals of the 3rd experimental group the densimetric examination of samples, staining by alcyan blue, showed a decrease in the optical density

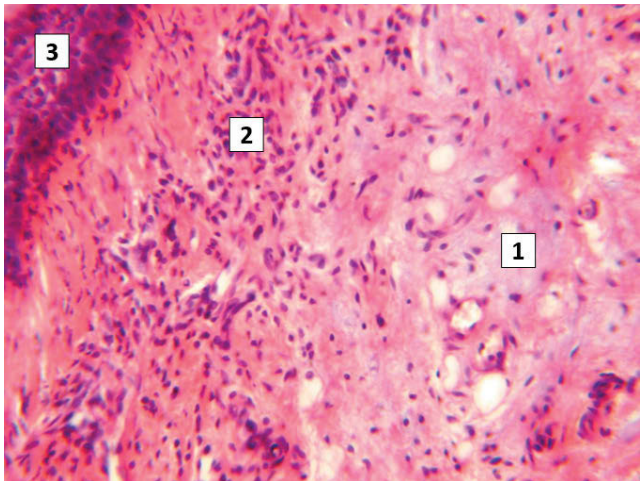

Fig. 4. Oral mucosa under conditions of insulin resistance on the background of iodine deficit
Staining: hematoxylin and eosin × 400
1 – mucous edema of the connective tissue of the mucous membrane, 2 – macrophage-leukocyte infiltration of connective tissue, 3 – intraepithelial macrophage-leukocyte infiltration

of connective tissue, in which the content of unsulfated glycosaminoglycans exceeded the analogical indicators in animals of the control group by 5.5 % ($p<0.05$). The connective tissue was covered with multilayered squamous epithelium with hyperplastic changes in most layers. Such changes were confirmed by morphometric analysis, which indicated an increase in the thickness of the granular layer and stratum corneum of the epithelium of oral mucosa in rats with combined endocrinopathy by 26.8-60.7 % ($p<0.05$) compared with the corresponding indexes in animals with isolated endocrine disease. Epitheliocytes were covered with a layer of keratin, the thickness of which was by 6.1 % ($p<0.05$) higher than correspondent index in animals with isolated ID, which was by 28.3 % ($p<0.05$) more than in rats of the control group. The changes in a vascular net of oral mucosa were noticed also. Thus, in some capillaries, small veins and arteries an increase in glycoproteins and more pronounced endothelial hypercellularity was found. The nuclei of such endothelial cells acquired an irregular circular shape and prolapsed into the lumen (Fig. 5).

CONCLUSIONS

The development of IR and ID is accompanied by the changes in the histological structure of oral mucosa, which can lead to disruption of the structure of periodontal tissues and the integral tooth-alveolar complex. The combined endocrinopathy leads to more pronounced changes in the mucous membrane, which should be considered in the complex treatment of patients with diabetes, hypothyroid dysfunction, and especially under conditions of their combination.

REFERENCES

1. Bagrii MM, Dibrova VA. [Methods of morphological research].Vinnytsya: Nova knyha. 2016. 328 p. [in

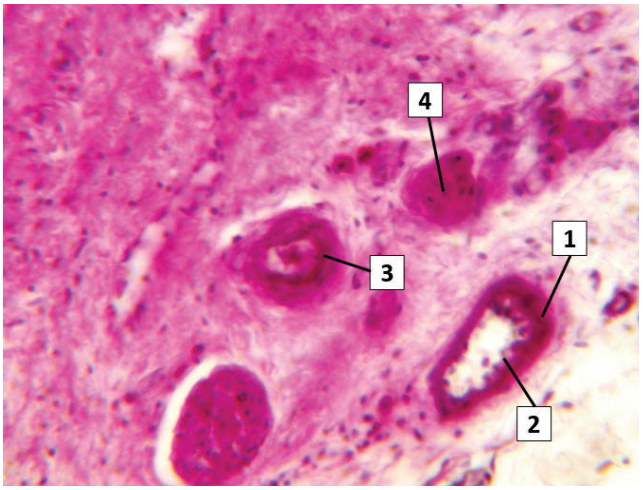

Fig. 5. The structure of vessels under conditions of insulin resistance on the background of iodine deficit. Staining: PAS × 400
1 – increase in glycoproteins in the venule wall, 2 – endothelium of venule, 3 – uneven accumulation of glycoproteins along the inner elastic membrane of the small artery, 4 – narrowing of the lumen of the small artery

Ukrainian]. URL: http://www.irbis-nbuv.gov.ua/cgi-bin/irbis_nbuv/cgiirbis_64.exe?I21DBN=LINK&P21DBN=UJRN&Z21ID=&S21REF=10&S21CNR=20&S21STN=1&S21FMT=ASP_meta&C21COM=S&2_S21P03=FILA=&2_S21STR=Morphology_2016_10_1_20

2. Godovanets O.I., Moroz A.V. [Dental pathology in children with endocrine diseases]. Clinical and Experimental Pathology. 2015;4(54):209-13. [in Ukrainian]. DOI 10.24061/1727-4338.XIV.4.54.2015.47. URL: http://cep.bsmu.edu.ua/article/view/1727-4338.XIV.4.54.2015.47
3. Kikhtyak O.P., Lishchuk O.Z., Moskva Kh.A. [Studying of the beneficial effect of insulin sensitizer on the carbohydrate and lipid metabolism in patients with diffuse toxic goiter and insulin resistance]. Achievements of Clinical and Experimental Medicine. 2016;4:51-5. [in Ukrainian]. DOI: https://doi.org/10.11603/1811-2471.2016.v0.i4.7077. URL: https://ojs.tdmu.edu.ua/index.php/zdobutky-eks-med/article/view/7077
4. Lishchuk O.Z. [The influence of metformin on the indices of thyroid panel, carbohydrate and lipid metabolism in patients with diffuse toxic goiter and insulin resistance]. International Journal of Endocrinology. Clinical Thyroidology. 2016;1(73):21-4. [in Ukrainian]. URL: http://www.irbis-nbuv.gov.ua/cgi-bin/irbis_nbuv/cgiirbis_64.exe?I21DBN=LINK&P21DBN=UJRN&Z21ID=&S21REF=10&S21CNR=20&S21STN=1&S21FMT=ASP_meta&C21COM=S&2_S21P03=FILA=&2_S21STR=Mezh_2016_1_5
5. Nechyporchuk V.M., Korda M.M. [Metabolism in Hypo- and Hyperthyroidism]. Herald Sci Research. 2015;3:4-7. [in Ukrainian]. DOI: 10.11603/1681-276X.2015.3.5170. URL: https://ojs.tdmu.edu.ua/index.php/visnyk-nauk-dos/article/view/8460
6. Pogrebnyak G.V. [Condition of the alveolar bone and gingival tissue in female rats under conditions of unbalanced diets]. World of biology and medicine. 2015;4(54):134-8. [in Ukrainian]. URL: https://cyberleninka.ru/article/n/stan-alveolyarnoyi-kistki-i-yasenevoyi-tkanini-u-samits-schuriv-za-umov-nesbalansovanih -ratsioniv-goduvannya
7. Disorders of uric acid metabolism in rats with fructose-induced experimental insulin resistance syndrome. Fiziologichnyi Zhurnal. 2011;57(1):72-81. [in Ukrainian]. DOI: https://doi.org/10.15407/fz57.01.072. URL: https://fz.kiev.ua/journals/2011_V.57/Fiziologichnyi%20Zhurnal%2057(1)_2011/Fiziologichnyi%20Zhurnal%2057(1)__2011_72-81.pdf
8. Voronych-Semchenko N.M., Huranych T.V. The changes of processes of free radical oxidation of lipids and proteins, antioxidant defence in rats with hypofunction of the thyroid gland in conditions of iodine and copper deficiency. Fiziologichnyi Zhurnal. 2014;60(4):30-9. DOI: https://doi.org/10.15407/fz60.04.030. URL: https://fz.kiev.ua/journals/2014_V.60/2014_4/30-39.pdf

Conflicts of interest: authors have no conflict of interest to declare.
Received: 12.11.2020
Revised: 18.12.2020
Accepted: 22.12.2020

СТРУКТУРНІ ЗМІНИ СЛИЗОВОЇ ОБОЛОНКИ ПОРОЖНИНИ РОТА У ЩУРІВ ІЗ ІНСУЛІНОРЕЗИСТЕНТНІСТЮ, ЙОДОДЕФІЦИТОМ ТА ЗА УМОВИ ЇХ ПОЄДНАННЯ

Гуранич С. П., Воронич-Семченко Н. М., Багрій М. М.

Івано-Франківський національний медичний університет, Івано-Франківськ, Україна
guranichtanja@ukr.net

Актуальність. Взаємозв'язок між ендокринопатіями та станом органів ротової порожнини пов'язаний із розладами метаболізму, гемодинаміки, імунологічними й нейрорегуляторними порушеннями. Оскільки першою лінією контакту з середовищем порожнини рота є слизова оболонка, зміни її властивостей негативно впливають на функціональний стан інших тканин пародонту.

Ціль: вивчити структурні зміни слизової оболонки порожнини рота (СОПР) у щурів із комбінованою ендокринопатією.

Матеріали та методи. Дослідження проведені на 120 щурах, які були розділені на три дослідні (тварини із йододефіцитом – ЙД, інсулінорезистентністю – ІР, ІР на тлі ЙД) та контрольну групу тварин. Здійснювали гістологічне дослідження СОПР, комп'ютерну морфометрію та денситометрію об'єктів.

Результати. У щурів із ЙД епітелій слизової оболонки характеризувався розвитком акантозу, розширенням зернистого шару, посиленим кератиноутворенням. Розвиток ІР зумовив гіперпластичні зміни епітелію з формуванням невиражених акантотичних тяжів, епітеліальною базальною гіперклітинністю, що підтверджувалося морфометричними даними. За умов комбінованої ендокринопатії спостерігали більш виражені зміни гістологічної будови СОПР. Зокрема, відмічали розвиток слизового набряку у сполучній тканині, із переважно макрофагальною гіперклітинністю по периферії. Денситометричне дослідження препаратів вказувало на зменшення оптичної щільності сполучної тканини. Разом із тим спостерігали гіперпластичні зміни більшості шарів епітелію та виражені зміни судинної стінки.

Висновки. Комбінована ендокринопатія призводить до виражених змін СОПР, що може зумовити порушення структури тканин пародонта та цілісного зубо-альвеолярного комплексу.

Ключові слова: інсулінорезистентність, йододефіцит, слизова оболонка порожнини рота, гістологічні зміни.

ТСТРУКТУРНЫЕ ИЗМЕНЕНИЯ СЛИЗИСТОЙ ОБОЛОЧКИ ПОЛОСТИ РТА У КРЫС С ИНСУЛИНОРЕЗИСТЕНТНОСТЬЮ, ЙОДОДЕФИЦИТОМ И ПРИ ИХ СОЧЕТАНИИ

Гуранич С. П., Воронич-Семченко Н. Н., Багрий Н. Н.

Ивано-Франковский национальный медицинский университет, Ивано-Франковск, Украина
guranichtanja@ukr.net

Актуальность. Взаимосвязь между эндокринопатиями и состоянием органов ротовой полости обусловлена расстройствами метаболизма, гемодинамики, иммунологическими и нейрорегуляторными нарушениями. Поскольку первой линией контакта со средой полости рта является слизистая оболочка, изменения ее свойств негативно влияют на функциональное состояние других тканей пародонта.

Цель: изучить структурные изменения слизистой оболочки полости рта (СОПР) у крыс с комбинированной эндокринопатией.

Материалы и методы. Исследования проведены на 120 крысах, которые были разделены на три опытных (животные с йододефицитом – ЙД, инсулинорезистентностью – ИР, ИР на фоне ЙД) и контрольную группу животных. Проводили гистологическое исследование СОПР, компьютерную морфометрию и денситометрию объектов.

Результаты. У крыс с ЙД эпителий слизистой оболочки характеризовался развитием акантоза, расширением зернистого слоя, усиленным кератинообразованием. Развитие ИР обусловило гиперпластические изменения эпителия с формированием невыраженных акантотичних тяжей, эпителиальной базальной гиперклеточной инфильтрацией, что подтверждалось морфометрическими данными. В условиях комбинированной эндокринопатии наблюдали более выраженные изменения гистологического строения СОПР. В частности, отмечали развитие слизистого отека в соединительной ткани, с преимущественно макрофагами по периферии. Денситометрическое исследования препаратов указывало на уменьшение оптической плотности соединительной ткани. Вместе с тем наблюдали гиперпластические изменения большинства слоев эпителия и выраженные изменения сосудистой стенки.

Выводы. Комбинированная эндокринопатия приводит к выраженным изменениям СОПР, что может обусловить нарушение структуры тканей пародонта и целостного зубо-альвеолярного комплекса.

Ключевые слова: инсулинорезистентность, йододефицит, слизистая оболочка полости рта, гистологические изменения.

.

DOI: https://doi.org/10.32345/2664-4738.4.2020.02
UDC: 616.831-005.4-039.4-07.4"32":[616-022.7:578]

INCIDENCE OF CONFIRMED MANIFEST VIRAL INFECTION IN CASES OF ISCHEMIC STROKE, DEPENDING ON THE SEASON

[1]***Turchina N.S.*** (https://orcid.org/0000-0002-9992-4929)
[1]***Cherenko T.M.*** (https://orcid.org/0000-0003-0867-5929)
[2]***Trepet L.N.*** (https://orcid.org/0000-0001-8300-7117)
[3]***Rybalko S.L.*** (https://orcid.org/0000-0002-1913-1380)
[3]***Starosyla D.B.*** (https://orcid.org/0000-0003-0210-2361)

[1] Bogomolets National Medical University, Kyiv, Ukraine
[2] KNP «Olexadrovsk Clinical Hospital», Kyiv, Ukraine
[3] SI «Gromashevsky Institute of Epidemiology and Infectious Diseases National Academy of Medical Sciences of Ukraine», Kyiv, Ukraine
tcherenko@ukr.net

Relevance. Seasonal differences in stroke incidence are associated with various physical factors, some associated with pathophysiological changes in the body leading to ischemic stroke. At the same time, there is little research into the differences in the frequency of detection of the genome of herpes virus infection and influenza virus, depending on the season.

Objective. Investigate the existence of associations between the season and the frequency of virologically confirmed herpezoid infection manifested by herpezoid virus and influenza virus of patients with ischemic stroke.

Materials and methods. In the period from 01.01.2017 to 31.12.2017. during the year at the bases of the neurological and department of the Alexandrovsky Clinical Hospital Centre. Kyiv conducted a study of 144 cases of cerebral ischemic stroke with medium-severe neurological deficit: 78 (54.2%) women and 66 (45.8%) men, with an average age of 63.1 0.8 years. Neurological examination and identification of the genome of herpes viruses and influenza virus, performed with the help of a polymerase chain reaction (PCR), was carried out monthly in 12 patients hospitalized by ambulance. Account was taken of the presence of a viral manifestation if it preceded the stroke within 2 weeks.

Results. 36 cases were examined each season. The ratio of men to women was 45.8 / 54.2 in total and did not differ between seasons, p = 0.514. 32 (22.2 per cent) patients have demonstrated a viral infection. In winter, 11 (34.4 per cent), in spring, 7 (21.9 per cent), in summer, 4 (12.5 per cent), in autumn, 10 (31.3 per cent) and all p. At the same time, during the summer period, the incidence of viral manifestation was definitely lower than in winter, p = 0.042. Virus genomes were found in 12 (33.3 per cent) patients in winter, 7 (19.4 per cent) in spring, 5 (13.9 per cent) in summer, 12 (33.3 per cent) in autumn and p = 0.131 rice. During the summer period, the frequency of PCR-confirmed herpes virus infection was definitely lower than in the winter-autumn season, p = 0.033.

Conclusions. Viral manifestations of herpes and influenza virus in the blood are more frequent during the winter and autumn periods; the frequency of detection indicated viral infection from October to January is reliably higher than the rate from March to August inclusive.

In 25.0 per cent of patients with ischemic stroke, the genome of herpes viruses and influenza virus in the blood is detected. In the event of a demonstration, the frequency of the above-mentioned viral infection is clearly higher (90.6 per cent as against 9.4 per cent) than that of patients without it.

Keywords: ischemic stroke, herpes virus, flu virus, season.

RELEVANCE

Data from the scientific literature, world experience indicate an increase in the prevalence of cerebrovascular disease (CVD) among the population of most countries, as well as their severe medical, demographic and socio-economic consequences [1-3]. To develop effective strategies for stroke prevention, it is necessary to continue the search for new, non-traditional risk factors, which include viral infection [4].

Numerous foreign studies suggest that latent viral infections may be predictors of ischemic cerebral stroke (ICS) [5-7]. The accumulation of infectious agents is obvious, which can play the role of triggers of the inflammatory process. In most cases, the development of CVD is influenced by the association of viral infection and other risk factors [8-10]. An important contribution in this aspect of environmental factors, climatic factors. Depending on the season, many works are devoted to the frequency of stroke, mainly by foreign authors [11-13].

An in-depth understanding of the role of the infectious factor that precedes a transient ischemic attack and IS, and often determines their development, is important for the development of preventive measures and improvement of treatment of acute cerebrovascular disorders (ACD) [14,15].

In the domestic literature there are isolated works on the influence of seasonality only on the spread of enterovirus infection [16].

Objective: Investigate the existence of associations between the season and the frequency of virologically

confirmed herpezoid infection manifested by herpezoid virus and influenza virus of patients with ischemic stroke.

MATERIALS AND METHODS

The study was conducted during the year from 01.01.2017 to 31.12.2017 on the basis of the neurological department and the department of cerebrovascular pathology of the Alexandrovsky Clinical Hospital Centre in Kyiv. The study included 144 patients with ischemic stroke: 78 (54.2%) women and 66 (45.8%) men. The mean age of patients was 63.1±0.8 years (from 41 years to 81 years).

In each season for the presence of viruses were examined 36 patients who were hospitalized by ambulance: 12 patients per month (3 patients per week), in the order of admission to the hospital.

Inclusion criteria: primary ischemic stroke, confirmed by MRI/CT scan, neurological score according to NIHSS [17] 8-16 points. The pathogenetic subtype was determined according to TOAS criteria [18], namely: atherothrombotic, cardioembolic, lacunar.

Criteria for non-inclusion in the study were: recurrent stroke, inability to collect a history of the patient, NIHSS score over 17, indeterminate pathogenetic subtype of stroke, lack of informed consent for virological examination.

All patients were diagnosed with a history of viral infection (two weeks before ACD), which was assessed by clinical signs of respiratory disease with runny nose, fever and fever, signs of intoxication, herpetic rashes of the lips and nose, available, herpeszoster.

Herpes viruses (HSV1, HSV2, VZV, CMV, EBV, HHV6) and influenza virus were detected.

Detection of herpesvirus DNA was performed by polymerase chain reaction (PCR). Herpesvirus DNA was isolated from cells using a DNA-sorb-BDNAkit reagent kit (AmpliSens, Russia) or innuPREPVirusDNAKit (AnalitykJenaAC, Germany) according to the manufacturer's instructions. The DNA concentration was determined spectrophotometrically using a Biophotometer (Eppendorf, Germany). DNA detection was performed by semi-quantitative PCR, using a set of reagents «AmpliSens®» (AmpliSens, Russia) according to the manufacturer's recommendations. Each sample analyzed by PCR contained 50 ng of DNA. The amplification products and GeneRuler ™ DNALadderMix (Fermentas, Lithuania) were analyzed in a 1.7% agarose gel containing 0.01% ethidium bromide. Digital images of PCR products were obtained in UV light of a transilluminator using a CanonDigitalIXUS 80IS camera. Analysis of digital images was performed using GelImager software (DNA-technology, Russia). In addition, RT-PCR was performed using the AmpliSens kit (AmpliSens, Russia) and EBARPOL (NPF Litech LLC, Russia), according to the manufacturer's recommendations (qTOWER 2.2 amplifier, Germany). Detection of influenza virus PNA was performed by PCR. Influenza virus RNA from cells was isolated using a set of reagents in real time (Real-TimeRT-PCR), using the technique of multiplex TaqManReal-TimeRT-PCR analysis, primers and TaqMan-probes, part of the domestic test system «DIANfluen» .

Statistical processing of the obtained results was performed using the statistical analysis program IBMSPSS Statistics Basev.22. Descriptive statistics were used, comparisons of two independent groups on average values were performed using the Mann-Whitney U-test, on a qualitative basis – using Pearson's $\chi 2$. The null hypothesis regarding the equality of variables was rejected at $p < 0.05$.

RESULTS AND THEIR DISCUSSION

The ratio of men and women was generally 45.8/54.2 and did not differ between seasons, p=0.80 (Table 1).

The mean age of patients was 63.1±0.8 years (from 41 years to 81 years). There were no significant differences in mean age between seasons (Fig. 1).

Table 1

Distribution of patients by gender depending on the season of the year

Season	Sex				Total	
	Women		Men			
	absolute	%	absolute	%	absolute	%
Winter	17	47,2	19	52,8	36	100,0
Spring	20	55,6	16	44,4	36	100,0
Summer	21	58,3	15	41,7	36	100,0
Autumn	20	55,6	16	44,4	36	100,0
Total	78	54,2	66	45,8	144	100,0

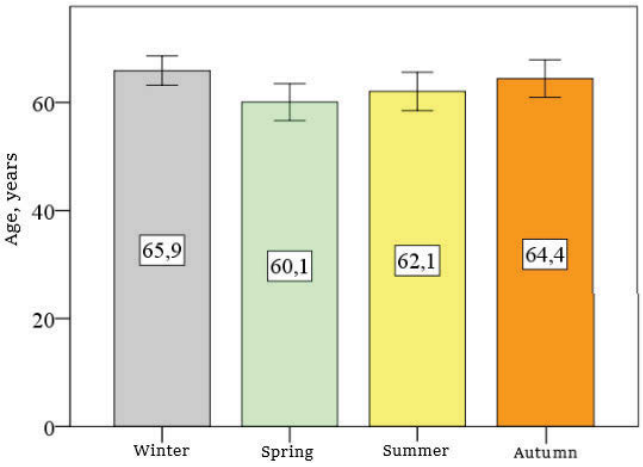

Fig. 1. The average age of patients with a 95% confidence interval at different times of the year (all p> 0.05)

Atherothrombotic (AT) subtype of stroke had 73 (50.7%) of patients, cardioembolic (CE) – 48 (33.3%), lacunar – 23 (16.0%).

The distribution of patients by stroke subtype did not differ significantly depending on the season (p = 0.886), there was only a tendency to increase the percentage of AT subtype in autumn – 58.3%, and KE – in spring (41.7%), which did not differ from blood pressure (Fig. 2).

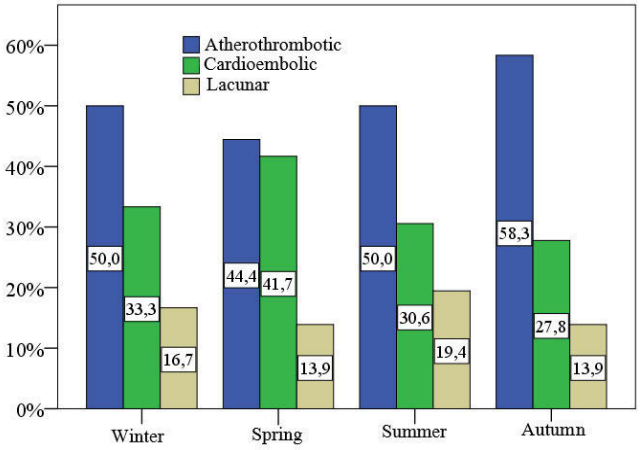

Fig. 2. Distribution of patients by pathogenetic subtype of stroke depending on the season

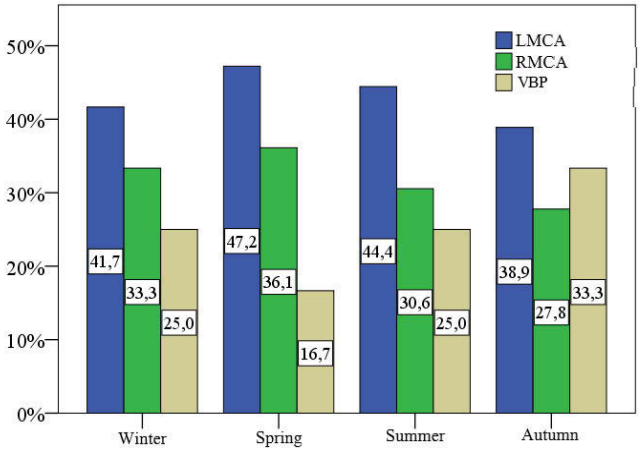

Fig. 3. Distribution of patients by the pool of lesions depending on the season (LMCA – left middle cerebral artery, RMCA – right middle cerebral artery, VBP – vertebro-basilar pool).

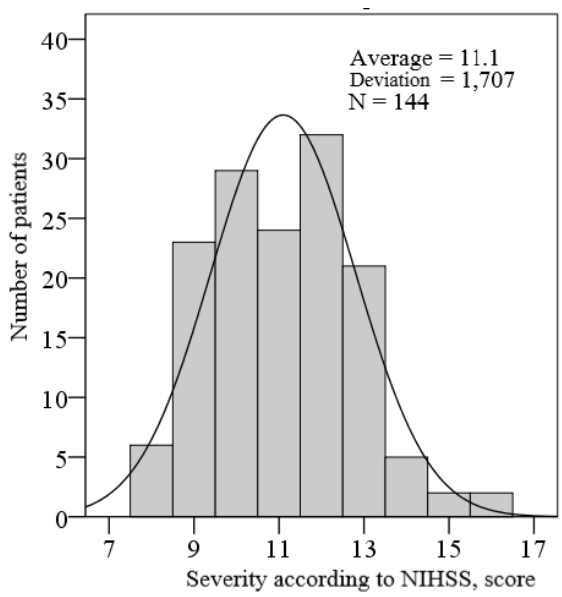

Fig. 4. Distribution of patients by score according to the scale NIHSS

Ischemic stroke occurred in the pool of the left middle cerebral artery (LMCA) in 62 (43.1%) patients, the right middle cerebral artery (RMCA) – 46 (31.9%), in the vertebro-basilar pool (VBP) – 36 (25,0%). The distribution of patients in the pool of the affected vessel also did not differ significantly depending on the season (p=0.839) (Fig. 3).

The severity of neurological deficits on the NIHSS scale averaged 11.1±0.16 points: from 8 to 16 points (Fig. 4).

The severity of neurological deficits of the studied patients on the NIHSS scale did not differ significantly at different times of the year, and was 10.9±0.3 in winter; 10.7±0.2 in spring; 11.4 ±0.2 in summer and 11.2 ±0,2 in autumn (Fig. 5).

Clinical manifestation of acute respiratory viral infection and influenza was found in 32 (22.2%) patients. In winter it was in 11 (30.6%) patients, in spring – in 7 (21.9%), in summer – in 4 (11.1%), in autumn – in 10 (27.8%) (Fig. 6).

There were no statistically significant differences in the frequency of viral manifestations in winter, spring, autumn, all p>0.05. At the same time, in summer the frequency of viral infection was significantly lower

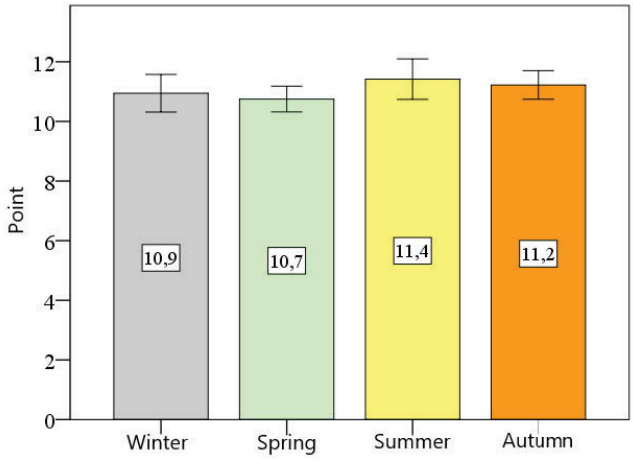

Fig. 5. The average score of patients on the NIHSS scale at different times of the year (all p> 0.05)

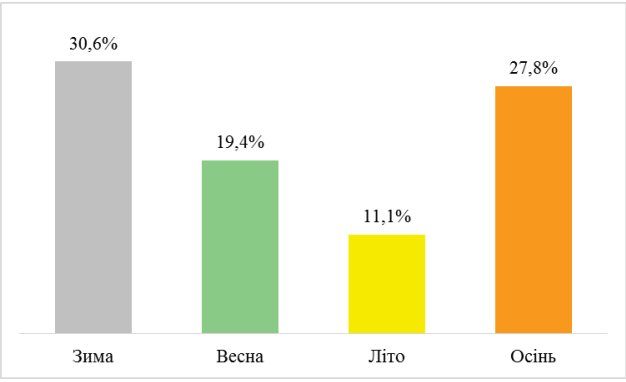

Fig. 6. Frequency of manifestation of viral infection in patients depending on the season

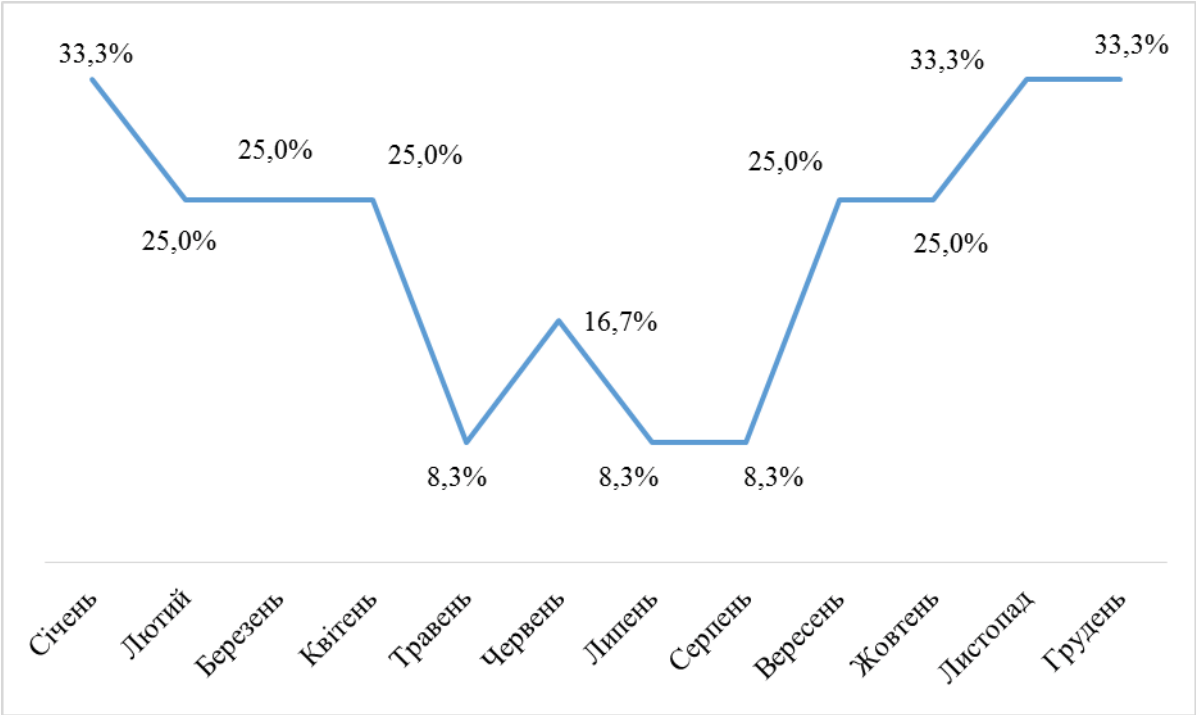

Fig. 7. Distribution of patients by frequency of viral infection by months of the year

compared to winter, p=0.042, and almost significantly lower compared to autumn, p=0.074.

The distribution of the incidence of viral infection in patients with ICS by months of the year showed approximately the same frequency: 33.3% was from November to January with a decrease to 25% in February, March, April, September, October and the lowest rates in May and summer months – 8.3% (Fig. 7).

Genomes of the herpesvirus family and influenza were detected in 36 (25%) patients with ICS. In particular, in 29 (90.6%) patients among those who had a viral manifestation (ie signs of acute viral infection or exacerbation of latent persistent herpes infection), and in 3 (9.4%) patients with ICS without viral manifestation (p=0.001) (Fig. 8).

The genomes of viruses in winter were found in 12 (33.3%) patients, in spring – in 7 (19.4%), in summer – in 5 (13.9%), in autumn – in 12 (33.3%)), p = 0.131 (Fig. 9).

Although in general there were no significant differences in the frequency of detection of viral infection by season (p=0.131), at the same time, in summer the frequency of detection of viral infection was significantly lower compared to the winter-autumn season, p=0.033. In addition, in the winter season there were significantly more patients with two or more types of viruses in associations compared to the summer season: 11 (30.6%) vs. 3 (8.3%), p = 0.017.

The frequency of detection of the genome of viruses in patients with ICS by months of the year was approximately the same from October to January – 33.3-41.7% (except February – 25.0%), an average of 35.0% with a decrease to 8.3-25.0% from March to August inclusive, on average 17.9%, p = 0.019 (Fig. 10).

Thus, this work continues a series of studies on the complex interaction of environmental factors, climatic conditions, seasonal influences and insufficiently studied non-traditional risk factors for stroke, with the hope of a significant shift in the prevention of ACD. There are many studies investigating, in particular, the effect of seasonal

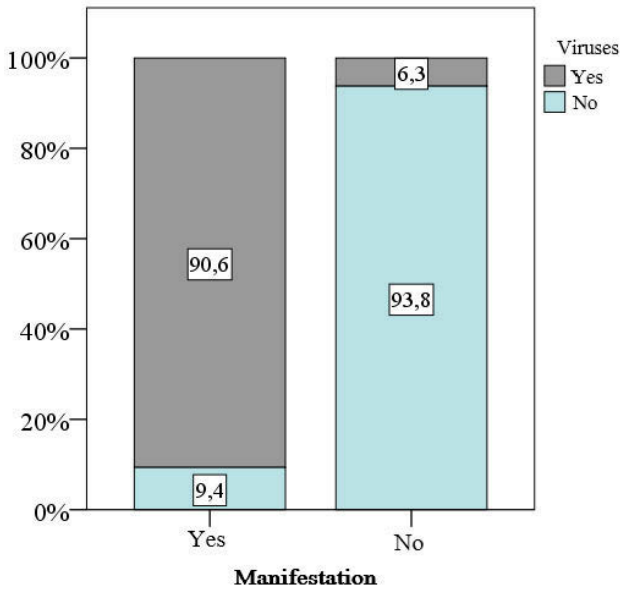

Fig. 8. The frequency of detection of the genome of viruses in patients with ACD depending on the presence of a viral manifestation

changes on the incidence of ischemic stroke, but their results are quite different [11-13], which can be partly explained by the lack of mandatory use of the Köppen climate zone classification [20]. As for the countries with a humid continental climate, which includes Ukraine, the latter aims to analyze the increase in the incidence of stroke in winter [21]. The aim of our study was to assess the contribution of infectious agents to the development of ICS, in particular latent herpes viruses, which are characterized by latent persistence, and influenza viruses, whose winter-spring outbreaks cause significant damage to public health and the economy.

We have shown a significantly higher percentage of patients with persistence of herpesviruses in winter compared to the summer season, and in winter the associations of two or more types of viruses were more often detected, which may indicate immunosuppressive tendencies in patients with cerebrovascular pathology. It is noteworthy the high percentage of detection of genomic herpesvirus infection (90.6%) in the case of its clinical manifestation, which may be useful for the selection of groups of patients - candidates for virological examination. Taking into account the common links in the pathogenesis of infectious inflammation and atherothrombotic stroke [22], we can assume a certain connection between the increase in the frequency of the viral trigger in the winter-autumn period and the higher frequency of ICS. Thus, the next question that clearly arises for family physicians is the prevention and treatment of exacerbations of herpesvirus infections to prevent stroke in at-risk groups.

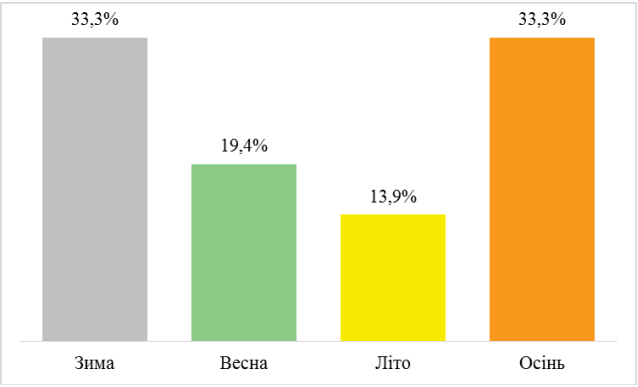

Fig. 9. The frequency of detection of viral infection in patients with ACD depending on the season

CONCLUSIONS.

Viral manifestations of herpes and influenza virus in the blood are more frequent during the winter and autumn periods; the frequency of detection indicated viral infection from October to January is reliably higher than the rate from March to August inclusive.

In 25.0 per cent of patients with ischemic stroke, the genome of herpes viruses and influenza virus in the blood is detected. In the event of a demonstration, the frequency of the above-mentioned viral infection is clearly higher (90.6 per cent as against 9.4 per cent) than that of patients without it.

REFERENCES

1. Catalá-López F., de Larrea-Baz N.F., Morant-Ginestar C., Álvarez-Martín E., Díaz-Guzmán J., Gènova-Maleras R. The national burden of cerebrovascular diseases in

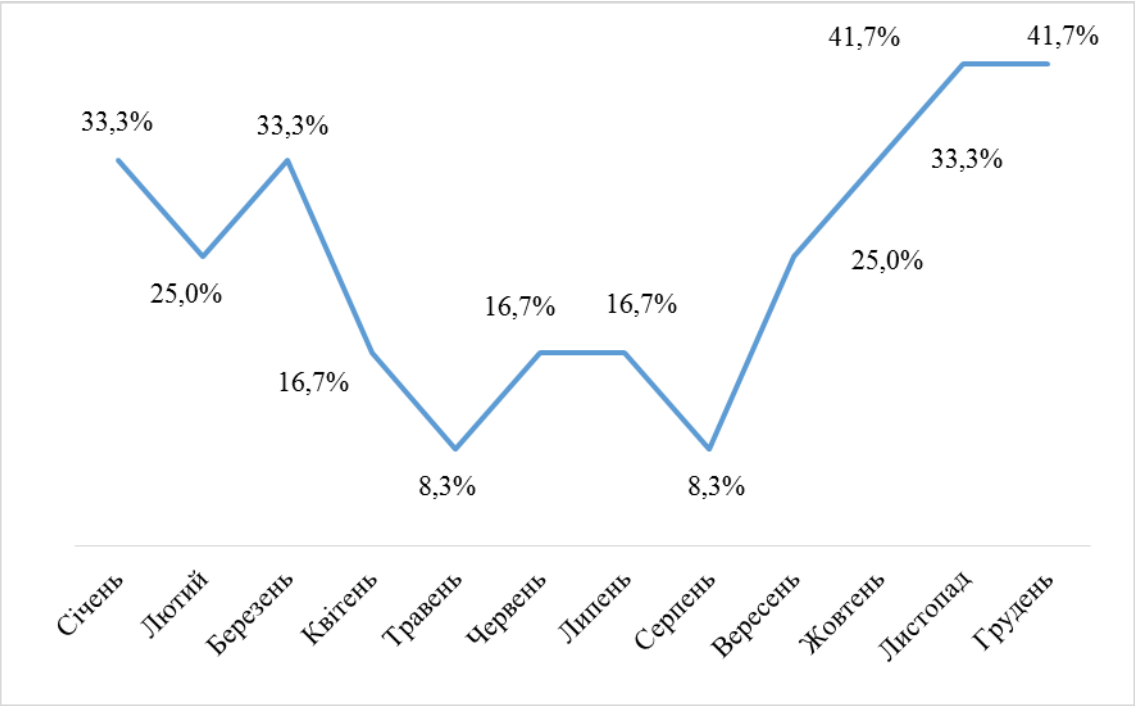

Fig. 10. Distribution of patients by frequency of detection of the genome of viruses by months of the year

Spain: a population-based study using disability-adjusted life years. Med. Clin. 2015 Apr 20; 144(8): 353-9. DOI: https://doi.org/10.1016/j.medcli.2013.11.040
2. Flicker L. Cardiovascular risk factors, cerebrovascular disease burden, and healthy brain aging. Clin. Geriatr. Med. 2010 Feb; 26(1): 17-27. DOI: https://doi.org/10.1016/j.cger.2009.12.005
3. G.A. Roth, C.O. Johnson, G. Nguyen, Naghavi M., Feigin V.L., Murray Ch.J.L., Forouzanfar M.H, Vos Th. Methods for estimating the global burden of cerebrovascular diseases. Neuroepidemiology. 2015; 45(3): 146-51. DOI: https://doi.org/10.1159/000441083
4. Forbes H.J., Williamson E., Benjamin L., Breuer J. Brown M.M., Langan S.M., Minassian C., Smeeth L., Thomas S.L., Warren-Gash Ch. Association of herpesviruses and stroke: Systematic review and meta-analysis. PLoS One. 2018 Nov 21; 13(11):e0206163. DOI: https://doi.org/10.1371/journal.pone.0206163
5. Wu Y.P., Sun D.D., Wang Y., Liu W., Yang J. Herpes Simplex Virus Type 1 and Type 2 Infection Increases Atherosclerosis Risk: Evidence Based on a Meta-Analysis. Biomed Res Int. 2016; 2016: Article ID 2630865. DOI: https://doi.org/10.1155/2016/2630865
6. Liu X.C., Guan Y.M., Hou L., Huang H., Liu H., Li Ch., Zhu Y., Tao X., Wang Q. The Short- and Long-Term Risk of Stroke after Herpes Zoster: AMeta-Analysis. Plos One. 2016 Oct 21. 11(10): e0165203. DOI: https://dx.doi.org/10.1371%2Fjournal.pone.0165203
7. Wang H., Peng G., Bai J.,He B., Kecheng H., Hu X., Liu D. Cytomegalovirus Infection and Relative Risk of Cardiovascular Disease (Ischemic Heart Disease, Stroke, and Cardiovascular Death): A Meta-Analysis of Prospective Studies Up to 2016. Journal of the American Heart Association. 2017 Jul; 6(7): e005025. DOI: https://doi.org/10.1161/JAHA.116.005025
8. Emsley H.C., Smith C.J., Tyrrell P.J., Hopkins S.J. Inflammation in acute ischemic stroke and its relevance to stroke critical care. Neurocrit. Care. 2008; 9(1): 125-38. DOI: https://doi.org/10.1007/s12028-007-9035-x
9. Rupprecht H.J., Blankenberg S., Bickel C., Rippin G., Hafner G., Prellwitz W., Schlumberger W., Meyer J. Impact of viral and bacterial infectious burden on long-term prognosis in patients with coronary artery disease. Circulation. 2001 Jul 3; 104(1): 25-31. DOI: https://doi.org/10.1161/hc2601.091703
10. Worthmann H., Tryc A.B., Deb M., Goldbecker A., Ma Y.T., Tountopoulou A., Lichtinghagen R., Weissenborn K. Linking infection and inflammation in acute ischemic stroke. Ann. NY Acad. Sci. 2010 Oct; 1207: 116-22. DOI: https://doi.org/10.1111/j.1749-6632.2010.05738.x
11. Wang H., Sekine M, Chen X., Kagamimori S. A study of weekly and seasonal variation of stroke onset. Int J Biometeorol. 2002 Dec; 47(1): 13-20. DOI:10.1007/s00484-002-0147-x
12. Palm F., Dos Santos M., Urbanek C., Greulich M., Zimmer K., Safer A., Grau A.J., Becher H. Stroke seasonality associations with subtype, etiology and laboratory results in the Ludwigshafen Stroke Study (LuSSt). Eur J Epidemiol. 2013 May; 28(5):373-81. DOI: https://doi.org/10.1007/s10654-013-9772-4
13. Karagiannis A., Tziomalos K., Mikhailidis P.D., Semertzidis P., Kountana E., Kakafika A.I., Pagourelias E.D., Athyros V.G. Seasonal variation in the occurrence of stroke in Northern Greece: A 10 year study in 8204 patients. Neurological Research. 2010. 32 (3): 326-331. DOI: https://doi.org/10.1179/174313208X331608
14. Warren-Gash C., Blackburn R., Whitaker H., McMenamin J., Hayward A.C. Laboratory-confirmed respiratory infections as triggers for acute myocardial infarction and stroke: a self-controlled case series analysis of national linked datasets from Scotland. Eur Respir J. 2018 Mar 29; 51(3):1701794. DOI: https://doi.org/10.1183/13993003.01794-2017
15. Esenwa C.C., Elkind M.S. Inflammatory risk factors, biomarkers and associated therapy in ischaemic stroke. Nature Reviews Neurology. 2016 Oct. 12(10):594-604. https://doi.org/10.1038/nrneurol.2016.125
16. Poniatovsky V.A., Bobyr V.V., Shirobokov V.P. [Wastewater treatment from enteroviruses and bacteriophages at the Bortnytska aeration station]. Microbiological Journal. 2014: 76(2): 53-8. [in Ukrainian] URL: http://microbiolj.org.ua/images/files/magazine/2014/2/2014_76_2_09_Ponyatovsky.pdf
17. Odderson I.R. The National Institutes of Health Stroke Scale and its importance in acute stroke management. Phys Med Rehabil Clin N Am. 1999 Nov: 10(4):787-800. PMID: 10573707. URL: https://pubmed.ncbi.nlm.nih.gov/10573707/
18. Kolominsky-Rabas P.L., Weber M., Gefeller O., Neundoerfer B., Heuschmann P.U. Epidemiology of ischemic survival in ischemic strokesubtypes: A population-based study. Stroke. 2001 Dec 1; 32(12):2735-40. DOI: https://doi.org/10.1161/hs1201.100209
19. Emsley H.C., Hopkins S.J. Acute ischaemic stroke and infection: recent and emerging concepts. Lancet Neurol. 2008 Apr; 7(4): 341-53. DOI: https://doi.org/10.1016/s1474-4422(08)70061-9
20. McKnight T.L, Hess D. Climate Zones and Types: The Köppen System. In: Physical Geography: A Landscape Appreciation – Upper Saddle River, NJ: Prentice Hall, 2000. P. 200-201. URL: https://www.worldcat.org/title/physical-geography-a-landscape-appreciation/oclc/43724491
21. Li Y., Zhou Z., Chen N., He L., Zhou M. Seasonal variation in the occurrence of ischemic stroke: A meta-analysis. Environ Geochem Health. 2019 Oct; 41(5): 2113-2130. DOI: https://doi.org/10.1007/s10653-019-00265-y
22. Bogousslavsky J., Kaste M., Olsen T.S., Hacke W., Orgogozo J.M. Risk factors and stroke prevention. European Stroke Initiative (EUSI). Cerebrovasc. Dis. 2000; 10(suppl. 3): 12-21. DOI: https://doi.org/10.1159/000047577

Conflicts of interest: authors have no conflict of interest to declare.
Received: 20.08.2020
Revised: 25.11.2020
Accepted: 21.12.2020

ЧАСТОТА ВИЯВЛЕННЯ ПІДТВЕРДЖЕНОЇ МАНІФЕСТНОЇ ВІРУСНОЇ ІНФЕКЦІЇ У ХВОРИХ З ІШЕМІЧНИМ ІНСУЛЬТОМ В ЗАЛЕЖНОСТІ ВІД СЕЗОНУ РОКУ

[1]Турчина Н.С., [1]Черенько Т.М., [2]Трепет Л.М., [3]Рибалко С.Л., [3]Старосила Д.Б.

[1] Національний медичний університет імені О.О. Богомольця, Київ, Україна
[2] КНП «Олександрівська клінічна лікарня», Київ, Україна
[3] ДУ «Інститут епідеміології та інфекційних захворювань імені Л.В. Громашевського НАМН України», Київ, Україна
tcherenko@ukr.net

Актуальність. Сезонні відмінності у частоті захворюваності на інсульт пов'язують з різними фізичними природними факторами, деякі з них асоціюються з патофізіологічними змінами в організмі, що призводять до розвитку ішемічного інсульту. Водночас практично не досліджено, чи існують відмінності в частоті виявлення геному герпесвірусної інфекції та вірусу грипу залежно від сезону року.

Мета роботи. Дослідити наявність асоціацій між порою року та частотою підтвердженої маніфестної герпесвірусної інфекції та вірусу грипу пацієнтів з ішемічним інсультом.

Матеріал та методи. В період з 01.01.2017 р. до 31.12.2017 р . протягом року на базах неврологічного відділення та відділення церебро-васкулярної патології Олександрівської клінічної лікарні м. Києва виконувалось дослідження 144 хворих на мозковий ішемічний інсульт (МІІ) із середньо-тяжким неврологічним дефіцитом: 78 (54,2 %) жінок та 66 (45,8 %) чоловіків, із середнім віком хворих 63,1±0,8 роки. Неврологічне обстеження та виявлення геному герпесвірусів та вірусу грипу, що здійснювалось за допомогою полімеразної ланцюгової реакції (ПЛР), проводилось щомісяця у 12 хворих, госпіталізованих за швидкою допомогою. Враховували наявність маніфестації вірусної інфекції, якщо вона передувала МІІ протягом двох тижнів.

Результати. В кожний сезон року було обстежено 36 хворих. Співвідношення чоловіків та жінок становило в цілому 45,8/54,2 та не відрізнялося між сезонами, p=0,514. Маніфестація вірусної інфекції встановлена у 32 (22,2%) хворих. З них: у зимовий період – у 11 (34,4 %) хворих, у весняний – у 7 (21,9 %), у літній – у 4 (12,5 %), в осінній – у 10 (31,3 %), всі p>0,05. Водночас, у літній період частота маніфестації вірусної інфекції була достовірно меншою порівняно із зимовим періодом, p=0,042. Геноми вірусів у зимовий період виявлено у 12 (33,3 %) хворих, у весняний – у 7 (19,4 %), у літній – у 5 (13,9 %), у осінній – у 12 (33,3 %), p=0,131. У літній період частота підтвердженої за допомогою ПЛР герпесвірусної інфекції була достовірно меншою порівняно з зимово-осіннім сезоном, p=0,033.

Висновки. Вірусологічно підтверджена маніфестація герпесвірусів та вірусу грипу в крові частіше відмічається в зимовий та осінній періоди; частота виявлення зазначеної вірусної інфекції з жовтня до січня достовірно переважає аналогічний показник з березня до серпня включно.

У 25,0 % хворих з ішемічним інсультом виявляється геном герпесвірусів та вірусу грипу в крові. За умов клінічної маніфестації (22,2 % хворих), частота зазначеної вірусної інфекції достовірно вище (90,6 % проти 9,4 %), ніж у хворих без маніфестації.

Ключові слова: ішемічний інсульт, герпесвірусна інфекція, вірус грипу, сезон року.

ЧАСТОТА ВЫЯВЛЕНИЯ ПОДТВЕРЖДЁННОЙ МАНИФЕСТНОЙ ВИРУСНОЙ ИНФЕКЦИИ У БОЛЬНЫХ С ИШЕМИЧЕСКИМ ИНСУЛЬТОМ В ЗАВИСИМОСТИ ОТ СЕЗОНА ГОДА

[1]Турчина Н.С., [1]Черенько Т.М., [2]Трепет Л.Н., [3]Рыбалко С.Л., [3]Старосила Д.Б.

[1] Национальный медицинский университет имени А.А. Богомольца, Киев, Украина
[2] КНП «Александровская клиническая больница», Киев, Украина
[3] ГУ «Институт эпидемиологии и инфекционных заболеваний имени Л.В. Громашевского НАМН Украины», Киев, Украина
tcherenko@ukr.net

Актуальность. Сезонные различия в частоте заболеваемости инсультом связывают с различными физическими природными факторами, некоторые из них ассоциируются с патофизиологическими изменениями в организме, приводящими к развитию ишемического инсульта. В то же время, практически не исследовано, существуют ли различия в частоте выявления генома герпесвирусной инфекции и вируса гриппа в зависимости от сезона года.

Цель: исследовать наличие ассоциаций между временем года и частотой вирусологически подтвержденной манифестной герпевирусной инфекцией и вирусом гриппа у пациентов с ишемическим инсультом.

Материалы и методы. В период с 01.01.2017 г. до 31.12.2017 г. в течение года на базах неврологического отделения и отделения церебро-васкулярной патологии Александровской клинической больницы Киева выполнялось исследование 144 больных с мозговым ишемическим инсультом (МИИ) со средне-тяжелым неврологическим дефицитом: 78 (54,2%) женщин и 66 (45,8%) мужчин, средний возраст больных 63,1±0,8 года. Неврологическое обследование и выявление генома герпесвирусов и вируса гриппа осуществлялось с помощью полимеразной цепной реакции (ПЦР) и проводилось ежемесячно у 12 больных, госпитализированных по скорой помощи. Учитывали наличие манифестации вирусной инфекции, если она предшествовала МИИ в течение двух недель.

Результаты. В каждый сезон года было обследовано 36 больных. Соотношение мужчин и женщин составило в целом 45,8 / 54,2 и не отличалось между сезонами, p = 0,514. Манифестация вирусной инфекции установлена у 32 (22,2%) больных. В зимний период – у 11 (34,4%), в весенний – у 7 (21,9%), в летний – у 4 (12,5%), в осенний – у 10 (31,3%) больных, все p <0,05. В то же время, в летний период частота манифестации вирусной инфекции была достоверно меньше по сравнению с зимним периодом, p = 0,042. Геномы вирусов в зимний период выявлено у 12 (33,3%) больных, в весенний – у 7 (19,4%), в летний – у 5 (13,9%), в осенний – у 12 (33,3%), p = 0,131. В летний период частота подтвержденной с помощью ПЦР герпесвирусной инфекции была достоверно меньше по сравнению с зимне-осенним сезоном, p = 0,033.

Выводы. Вирусологически подтвержденная манифестация герпесвирусов и вируса гриппа в крови чаще отмечается в зимний и осенний периоды; частота выявления указанной вирусной инфекции с октября по январь достоверно превышает аналогичный показатель с марта по август включительно.

У 25,0% больных с ишемическим инсультом выявляется геном герпесвирусов и вируса гриппа в крови. В условиях манифестации частота указанной вирусной инфекции достоверно выше (90,6% против 9,4%), чем у больных без ее наличия.

Ключевые слова: ишемический инсульт, герпесвирусная инфекция, вирус гриппа, сезон года.

DOI: https://doi.org/10.32345/2664-4738.4.2020.03
UDC 616.379-008.64:616.153.454

PROGRESSION OF DIABETIC NON-PROLIFERATIVE RETINOPATHY IN TYPE 2 DIABETES MELLITUS: THE CONNECTION WITH THE BLOOD ENDOTHELIAL MONOCYTE-ACTIVATING POLYPEPTIDE-II LEVEL

[1]***Rykov S.O.*** (https://orcid.org/0000-0002-3495-7471)
[1]***Korobov K.V.*** (https://orcid.org/0000-0001-8277-1674)
[1]***Mogilevskyy S.Yu.*** (https://orcid.org/0000-0002-8744-3124)
[2]***Ziablitsev D.S.*** (https://orcid.org/0000-0002-2671-2343)

[1]*Shupik National Medical Academy of Postgraduate Education, Kyiv, Ukraine*
[2]*Bogomolets National Medical University, Kyiv, Ukraine*
denis898@ukr.net

Relevance. The numerous pro-inflammatory and antiangiogenic properties of endothelial monocyte-activating polypeptide-II (EMAP-II) suggest its possible role in the onset and progression of diabetic non-proliferative retinopathy (DNPR) in type 2 diabetes mellitus (T2DM).

Objective – is to determine the blood EMAP-II in the DM2 patients and to establish its connection with the progression of DNPR.

Material and methods. We examined 91 patients with DM2 (182 eyes), who were divided into groups: 1st – there was no DNPR in both eyes and 2nd – there were no retinopathy in one eye, and isolated vascular anomalies were noted in the other (ETDRS level 14, 15). The control group included 25 patients of the corresponding age and gender. The patients were re-examined after 1 year. The level of EMAP-II was determined by the enzyme immunoassay in blood plasma once at the beginning of the study. Statistical packages MedStat and MedCalc v.15.1 (MedCalc Software bvba) were used for statistical research.

Results. The analysis of clinical and laboratory parameters showed that the initial manifestations of diabetic retinal lesions were manifested in 27.5% of patients after 7.16±1.11 years and were accompanied by greater glycemia. The level of EMAP-II in DM2 was many times higher than in the control, which depended on the presence of diabetic vascular changes in the retina: in patients without changes in the retina (group 1) – by 3.7 times, and in patients with initial vascular anomalies (group 2) – 5.2 times ($p<0.001$). The level of EMAP-II at the beginning of the study was associated with the progression of diabetic changes in the retina after 1 year – with their presence, it was 1.5 times higher than without them ($p<0.001$). Stratification by stage of DNPR after 1 year also showed the dependence of the severity of diabetic changes in the retina on the initial level of EMAP-II: in the presence of single vascular anomalies and initial DNPR, it was increased by 3-4 times, while with moderate DNPR – 5.9 times ($p<0.001$ for all comparisons).

Conclusion. Thus, a significant increase in the level of EMAP-II in T2DM was established and the dependence of the initial diabetic changes in the retina and the degree of their progression in 1 year after the increasing of the blood EMAP-II level.

Key words: diabetic nonproliferative retinopathy, type 2 diabetes mellitus, EMAP-II.

Relevance. The current state of the epidemiology of type 2 diabetes mellitus (DM2) is characterized by a progressive increase in morbidity along with a high rate of disability [1]. The number of patients in the world has more than quadrupled in the last 40 years [2, 3]. According to the International Diabetes Federation (IDF), the incidence forecast for 2045 will be 629 million people [4]. In 2017, 1.27 million patients were registered in Ukraine, and in 2019 – 1.5 million [5]. At the same time, almost 94 million people in the world have eye damage caused by diabetes [6].

DM2 is considered as a disorder of carbohydrate metabolism, the basis of which is tissue insensitivity to insulin (insulin resistance) on the background of chronic hyperglycemia [3, 4]. The latter is the main pathogenic factor in the development of micro- and macrovascular complications [7, 8]. The most common and early complication of DM2 is retinal vascular microangiopathy – diabetic retinopathy [9, 10]. This level is determined by a modified ETDRS scale in the system of clinical signs Airlie House [11]. In DNPR, the following signs are present in the retina: microaneurysms (MA) and microhemorrhages (MH), intraretinal microvascular abnormalities (IRMA), retinal venous abnormalities, and retinal nonperfusion. Their main causes are damage of the capillary endothelium with increased permeability and apoptosis, loss of pericytes, chronic inflammation [8, 9].

Over the last three decades, some attention has been paid to endothelial monocyte activating polypeptide-II (EMAP-II), which is a proinflammatory cytokine and chemoattractant for monocytes and granulocytes with potent antiangiogenic properties [12, 13]. Its precursor, proEMAP is identical to the p43 component of the tRNA multisynthetase complex and involved in protein translation. ProEMAP/p43 and EMAP-II act at many

levels and on many cell types, including endothelial cells, immune cells and fibroblasts.

EMAP-II has the ability to inhibit primary and metastatic tumor growth due to its potent effect on endothelial cells (by activating their apoptosis), reduces the expression of the main inducer of angiogenesis – vascular endothelial growth factor (VEGF) [14], inhibits the effects of hypoxia-inducible factor (HIF-1α) [15] and enhances the action of tumor necrosis factor (TNFα) [16]. EMAP-II binds to the α5β1-integrin receptor on the cell surface, leading to its internalization into the cytoplasm, where it interacts with its cytoplasmic partner PSMA7, a component of the proteasome degradation pathway. This interaction increases the degradation of HIF-1α, even under conditions of hypoxia, which inhibits its numerous proangiogenic effects [15].

The role of EMAP-II in initiating and maintaining the inflammatory response is extremely important – it is locally expressed near the site of injury, marking it as a «find me» signal for the recruitment of macrophages and neutrophils [12]. EMAP-II-mediated changes in macrophages which are induced mainly by signal transducer and transcription activator-3 (STAT3) and Janus-associated kinase (JAK) [17]. Inhibition of JAK1/2 and/or knockdown of STAT3 cancel the gene set, which is activated by EMAP-II. Activation of STAT3, mediated by EMAP-II, coincides with changes in the expression of pro- and anti-inflammatory genes in macrophages.

Thus, the complex of pro-inflammatory and anti-angiogenic properties of EMAP-II suggest its possible role in the occurrence and progression of initial vascular diabetic changes in DNPR.

Aim: to determine the blood EMAP-II level in the DM2 patients and to establish its connection with the progression of DNPR.

MATERIAL AND METHODS

We examined 91 patients (182 eyes) with DM2, aged 42 to 80 years, who were examined and treated on the basis of the Municipal Enterprise «Consultative and Diagnostic Center» Sviatoshyno district of Kyiv (Ukraine) and LTD «Ophthalmological Clinic «World of Vision», Kiev (Ukraine). The control group included 25 people aged 45 to 79 years who did not have diabetes and were examined for cataracts. The study was prospective, cohort, case-control. All subjects received informed consent to participate in the study.

At the time of the initial examination and after 1 year, all patients underwent conventional ophthalmological examinations, which included visometry, refractometry, tonometry, static perimetry, gonioscopy, biomicroscopy, and ophthalmoscopy. Ophthalmoscopy was performed using an aspherical Volk Super/Field lens (NC, USA) and a Goldman three-mirror contact lens. Also, all patients underwent spectral domain optical coherence tomography (OCT) on the device Optical Coherence Tomography 3D OCT-1000 (protocol Retina3D, RetinaRaster); also used OCT in the «Angio» mode (RetinaAngio protocol, wide 6x6 mm). Examination of the fundus was performed on a fundus camera, if necessary – with photography in 7 standard fields in accordance with the modified ETDRS system of clinical signs Airlie House [11]. The photographs studied the unified clinical signs of DR: MA and MH, IRMA, retinal venous abnormalities and retinal non-perfusion.

The level of EMAP-II was determined by enzyme-linked immunosorbent assay using BioSource reagent kits (USA) in blood plasma. Blood sampling was performed from the ulnar vein on an empty stomach in the level of 3 ml once at the time of the initial examination.

MedStat and MedCalc v.15.1 (MedCalc Software bvba) software packages were used for statistical research. The mean (M) and its standard deviation (SD) were calculated. Frequency (%) and its standard error (SE,%) were used for qualitative characteristics. In all cases, the differences were considered statistically significant at $p<0.05$.

RESULTS AND DISCUSSION

In this study, patients were divided into two groups (Table 1). In the 1st group (72.5% of people) at the beginning of the study DNPR was not in both eyes – paired eyes had no signs of diabetic damage, the ETDRS level was 10, which corresponded to the stage of "no retinopathy" [11]. The second group (27.5%) included patients who did not have DNPR in one eye ("no retinopathy" stage) and in the other – there were single vascular changes (ETDRS level was 14 or 15).

There was no difference between groups of patients by age and sex (p=0.201 and p=0.676, respectively). The

Table 1

Distribution of patients by groups

Groups of patients	Age, years	Sex		Disease duration, Years
		Male	Female	
Control	65,12±9,02	40,0±9,8%	60,0±9,8%	-
1st	68,41±7,78	30,3±5,7%	69,7±5,7%	4,20±2,23
2nd	66,76±7,39	32,0±9,3%	68,0±9,3%	7,16±1,11
Intergroup comparisons	F=1,62; p=0,201	χ^2=0,78; p=0,676		t=6,35; p<0,001

Notes: data display format: quantitative – M±SD; nominal – %±SE; F – Fisher's test for analysis of variance (ANOVA); χ2 – Pearson's criterion for comparing data distribution frequencies; t – Student's criterion for independent samples; p – probability of differences (taken at p<0,05).

duration of the disease was significant: patients in 2nd group (with the presence of diabetic retinal changes in one of the eyes) were sick, on average, three years longer, than those who did not have diabetic changes in the fundus (p<0,001). Analysis of carbohydrate metabolism showed a higher glycemia level in patients of 2nd group: 9.34±1.86 mmol/l against 7.87±2.15 mmol/l in 1st group (p=0.016).

Thus, the analysis of clinical and laboratory parameters showed that the initial manifestations of diabetic retinal lesions appeared in 27.5% of patients after 7.16±1.11 years, and were accompanied by higher glycemia.

The blood EMAP-II level in DM2 patients was many times higher than in the control (table. 2). Moreover, in patients without retinal changes – in 3.7 times, and in patients with initial manifestations of diabetic retinal lesions – in 5.2 times (p<0.001).

The difference between the patients groups was statistically significant (Fig. 1): in the 2nd group it was 1.4 times higher than in the 1st (p<0.001). This result confirmed the association of an increase in EMAP-II level with diabetic manifestations of retinal damage.

The next step was to examine the association of progression of diabetic retinal changes over 1 year with EMAP-II levels. Progression was understood as changes in the fundus towards deterioration with the development of diabetic vascular changes where they did not exist, either initial (ETDRS level 20) or moderate (ETDRS levels 35, 43, 47) DNPR (Table 3). In 1st group, progression was observed in 50.0% of patients, while in 2nd group – in 92.0% (p<0.001), which indicated

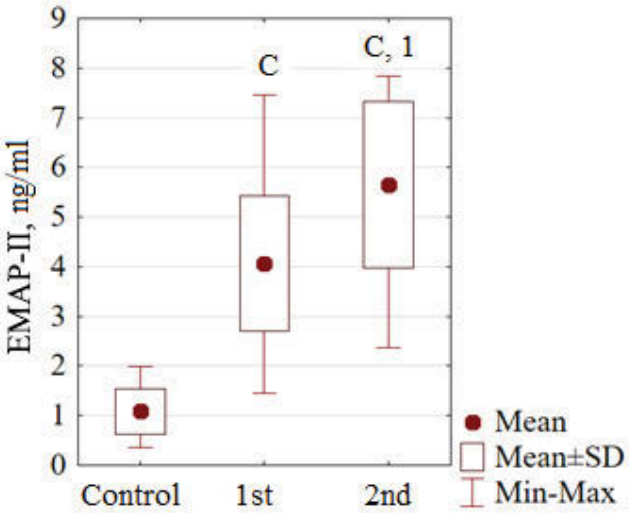

Fig. 1. The blood EMAP-II level in patients by groups. Probable differences are marked above the columns of the diagrams: C – with the control; 1 – with the 1st group (in all cases p<0,001).

Table 4

Blood EMAP-II level depending on the degree of progression of diabetic retinal changes after 1 year of observation (M±SD)

Indexes		Diabetic changes are absent (n=90)	Diabetic changes are present (n=92):			Intergroup comparisons
			single vascular abnormalities	initial DNPR	moderate DNPR	
		1	2	3	4	
EMAP-II, ng/ml		3,723±1,126	4,142±1,241	3,967±1,203	6,424±1,030	F=62,45; p<0,001
Post-hoc	1	–	p=0,604	p=0,882	p<0,001	–
	2	–	–	p=0,955	p<0,001	
	3	–	–	–	p<0,001	

Notes: data display format: M±SD; F - Fisher's test for analysis of variance (ANOVA); the Post-hoc lines show the probability of differences for paired (a posteriori) comparisons between these groups (1, 2, 3, 4) according to the Tukey HSD test for unequal in size samples; p – probability of differences (taken at p<0,05)

Table 2

Blood EMAP-II level by patient groups (M±SD)

Indexes	Control	Groups of patients		Intergroup comparisons
		1st	2nd	
EMAP-II, ng/ml	1,089±0,463	4,066±1,353	5,654±1,671	F=81,01; p<0,001
Post-hoc	Control	p<0,001	p<0,001	–
	1st group	–	p<0,001	

Notes: data display format: M±SD; F – Fisher's test for analysis of variance (ANOVA); the Post-hoc lines show the probability of differences for paired (a posteriori) comparisons between these groups according to the Tukey HSD test for unequal-sized samples; p – probability of differences (taken at p<0,05).

Table 3

Progression of diabetic retinal changes in groups of patients after 1 year

Progression:	Groups of patients		Intergroup comparisons
	1st	2nd	
is present (n=56)	50,00±6,15 %	92,00±5,43 %	χ^2=13,52; p<0,001
is absence (n=35)	50,00±6,15 %	8,00±5,43 %	

Notes: data display format: %±SE; χ2 – Pearson's criterion for comparing data distribution frequencies; p – probability of differences (taken at p<0,05).

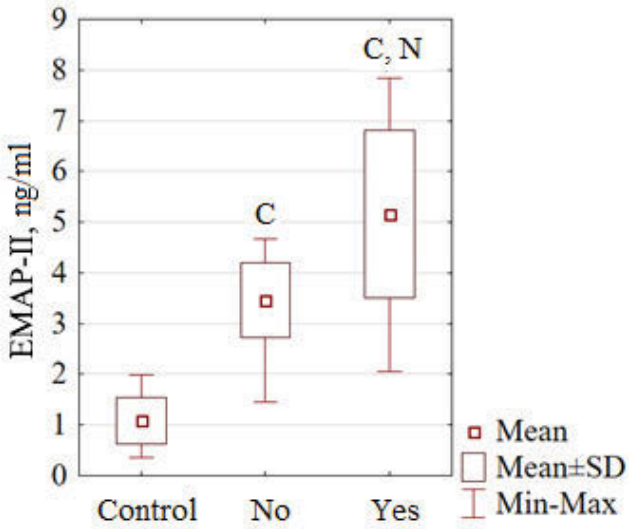

Fig. 2. The blood EMAP-II level in the control group (Control) and in patients with absence («No») and with presence («Yes») of progression. Probable differences are marked above the columns of the diagrams: C – with the control group; N – with patients without progression (in all cases p<0,001).

a significant tendency to progress in the presence of previous retinal damage in one of the eyes.

According to the presence or absence of progression, the level of EMAP-II was analyzed (Fig. 2). It was found that its level was 1.5 times higher (p<0.001) in the presence of progression of diabetic retinal changes than without them.

The EMAP-II level in the presence of diabetic retinal changes, as expected, significantly exceeded that in the control group (3.6-5.9 times; p<0.001). Among patients with different stages of DNPR, the maximum cytokine level was observed in the presence of moderate DNPR, while in patients with single vascular abnormalities (ETDRS 14/15) and initial DNPR (ETDRS 20), it was not significantly different (p=0.955).

Thus, stratification by the degree of diabetic retinal vascular changes after 1 year of observation showed the dependence of their severity on the initial blood EMAP-II level – the cytokine level in the initial DNPR was increased 3-4 times, while its highest level was observed in moderate DNPR (in 5.9 times). Interestingly, in patients without diabetic retinal changes, the level of EMAP-II was significantly increased. This confirms the primacy of the cytokine level shift in relation to the occurrence and progression of diabetic retinal changes.

Thus, the study found, firstly, – a significant increase in blood EMAP-II in DM2, and, secondly, – the dependence of the initial diabetic retinal changes and the degree of their progression after 1 year on the EMAP-II level increase. These results suggest an important role of this cytokine for the development of DNPR. The degree of increase in its level in the blood is a factor that precedes the development of DNPR, and there is a certain dose dependence of this effect.

The basis of microvascular abnormalities in chronic hyperglycemia in DM2 are mechanisms, such as enzymatic and non-enzymatic glycation of proteins, activation of the polyols shunt, which leads to intracellular edema, intensification of oxidative stress, activation of protein-kinase C [18]. Due to the thickening and loosening of intercellular matrix proteins of connective tissue and the basement membrane of capillaries, chronic inflammation is their hyalinization, which leads to loss of pericytes, destruction of endothelial cells and atrophy of capillaries. These pathological processes are combined into the concept of diabetic vasoregression, which determines the formation of DNPR from the first years of the disease [19].

The progression of pathological changes leads to sectoral occlusion of blood vessels and the formation of ischemic foci in the form of soft exudates, IRMA, MA and other manifestations characteristic of DNPR [20]. At this stage of the pathological process, the development of spontaneous MH, the source of which is damaged vessels of the microcirculatory rate.

In this light, it can be assumed that one of the causes of vasoregression is the activation of EMAP-II formation, which in the early stages is a compensatory response of retinal tissues to hypoxia and chronic inflammation caused by accumulation of Advance Glycation End Products (AGE) and oxidative stress [21]. Subsequently, the accumulation of EMAP-II can become a factor of damage. This assumption is confirmed in the results of this study.

Discussing the pathogenic effects of excessive accumulation of EMAP-II, in the first place we can note endothelial damage. It has been shown that under hypoxia, it increases the sensitivity of endothelial cells to apoptosis by activating the vesicular transport of TNF-R1 receptors to the cell membrane and facilitating the transmission of apoptotic signals by mobilization and membrane expression of the TNF-R1-Associated Death Domain [22]. In addition, EMAP-II enhances the expression of TNF-R1 by endothelial cells both in vitro and in vivo, which causes sensitization of the endothelium to the action of TNF [23]. This explains the close relationship between endothelial dysfunction and chronic inflammation in the pathogenesis of DNPR. Moreover, the specific effects of EMAP-II, which determine its antiagiogenic properties, at this stage contribute to the development of changes characteristic of DNPR and may inhibit the further development of proliferative diabetic retinopathy. The latter is associated with inhibition of VEGF and HIF-1α production, which may inhibit neoangiogenesis.

Results similar to those obtained in this work were highlighted in the study [24]. Serum EMAP-II levels were significantly elevated in patients with type 1 diabetes, especially in the presence of microvascular complications. At the same time, EMAP-II levels were directly related to inflammation, glycemic control, albuminuria and the risk of microvascular complications.

Also in DM2, a significant increase in the blood of EMAP-II level was found, which the author associates with the development of endothelial dysfunction due to chronic hyperglycemia [25]. The increase in EMAP-II level was directly correlated with the level of glycosylated hemoglobin, blood glucoses level, body mass index, total cholesterol, low-density lipoprotein, high-density lipoprotein, triglycerides.

CONCLUSIONS

1. The blood EMAP-II level in DM2 was many times higher than in the control, which depended on the presence of diabetic retinal vascular changes: in patients without retinal changes ("no retinopathy") – 3.7 times, and in patients with single retinal vascular abnormalities (ETDRS 14/15) – 5.2 times ($p<0.001$).

2. The initial blood EMAP-II level was associated with the progression of diabetic retinal changes after 1 year – in their presence it was 1.5 times higher than without them ($p<0.001$).

3. Stratification at the DNPR stages after 1 year also showed the dependence of the diabetic retinal changes severity on the initial EMAP-II level: in the presence of single vascular abnormalities and initial DNPR, it was increased 3-4 times, while in moderate DNPR – 5.9 times ($p<0.001$ for all comparisons).

REFERENCES

1. Heidemann C., Paprott R., Stühmann L.M., Baumert J., Mühlenbruch K., Hansen, Schiborn C., Zahn D., Gellert P., Scheidt-Nave Ch. Perceived diabetes risk and related determinants in individuals with high actual diabetes risk: results from a nationwide population-based survey. BMJ. Open Diabetes Res Care. 2019 Jun 21; 7(1):e000680. doi: 10.1136/bmjdrc-2019-000680.
2. Khan R.M., Chua Z.J., Tan J.C., Yang Y., Liao Z., Zhao Y. From pre-diabetes to diabetes: diagnosis, treatments and translational research. Medicina. Kaunas. 2019 Aug 29; 55(9): 546. doi: 10.3390/medicina55090546.
3. Lotfy M., Adeghate J., Kalasz H., Singh J., Adeghate E. Chronic complications of diabetes mellitus: a mini review. Curr Diabetes Rev. 2017; 13(1):3-10. doi: 10.2174/1573399812666151016101622.
4. Davies M.J., D'Alessio D.A., Fradkin J., Kernan W.N., Mathieu C., Mingrone G., Rossing P., Tsapas A., Wexler D.J., Buse J.B. Management of Hyperglycemia in Type 2 Diabetes, 2018. A Consensus Report by the American Diabetes Association (ADA) and the European Association for the Study of Diabetes (EASD). Diabetes Care. 2018 Dec; 41(12):2669-701. doi: 10.2337/dci18-0033.
5. Tronko M.D. [Priority issues of diabetology in Ukraine at the present stage and ways to solve them]. 2020 [Internet]. [cited 20.10.2020]. [in Ukrainian]. Available on: http://iem.net.ua/endocrinology_task/
6. Internetional Diabetes Federation and The Fred Hollows Fundation. Diabetes eye health: A guide for health care professionals. Brussel, Belgium: International Diabetic Federation [Internet]; 2015 [cited 15.07.20]; p. 10. Available on: https://idf.org/our-activities/care-prevention/eye-health/eye-health-guide.html#sub-content-tab-nav.
7. Nowak M.S., Grzybowski A. Rewie of the epidemiology of diabetic retinopathy [Internet]. Modern Retina. Ophtalmology Times. 2018 June 11. Available on: https://www.modernretina.com/diabetic-retinopathy/review-epidemiology-diabetic-retinopathy.
8. Kirsch S, Iroku-Malize T. Eye conditions in older adults: diabetic retinopathy. FP Essent. 2016 Jun;445:29-37; quiz 38-9. PMID: 27348530. Available on: https://pubmed.ncbi.nlm.nih.gov/27348530/
9. Safi H., Safi S., Ali H.-M., Hamid A. Early detection of diabetic retinopathy. Survey of Ophthalmology. 2018 Apr; 63 (5): 601-8. doi: 10.1016/j.survophthal.2018.04.003.
10. Voigt M., Schmidt S., Lehmann T., Köhler B., Kloos C., Voigt U.A., Meller D., Wolf G., Müller U.A., Müller N. Prevalence and Progression Rate of Diabetic Retinopathy in Type 2 Diabetes Patients in Correlation with the Duration of Diabetes. Exp Clin Endocrinol Diabetes. 2018 Sep; 126(9):570-6. doi: 10.1055/s-0043-120570.
11. Early Treatment Diabetic Retinopathy Study Research Group. Grading diabetic retinopathy from stereoscopic color fundus photographs – an extension of the modified Airlie house classification: ETDRS report № 10. Ophthalmology. 2020 Apr; 127(4S): 99-119. doi: 10.1016/j.ophtha.2020.01.030.
12. van Horssen R., Eggermont A.M., ten Hagen T.L. Endothelial monocyte-activating polypeptide-II and its functions in (patho)physiological processes. Cytokine Growth Factor Rev. 2006 Oct; 17(5):339-48. doi: 10.1016/j.cytogfr.2006.08.001.
13. Mogylnytska L.A. [Endothelial monocyte-activating polypeptide-II: properties, functions, and pathogenetic significance]. Fiziol. Zh. 2015; 61(1): 102-11. doi: 10.15407/fz61.01.102 [in Ukrainian]
14. Awasthi N., Schwarz M.A., Verma V., Cappiello C., Schwarz R.E. Endothelial monocyte activating polypeptide II interferes with VEGF-induced proangiogenic signaling. Lab Invest. 2009 Jan; 89(1):38-46. doi: 10.1038/labinvest.2008.106.
15. Tandle A.T., Calvani M., Uranchimeg B., Zahavi D., Melillo G, Libutti SK. Endothelial monocyte activating polypeptide-II modulates endothelial cell responses by degrading hypoxia-inducible factor-1alpha through interaction with PSMA7, a component of the proteasome. Exp Cell Res. 2009 Jul 1; 315(11):1850-9. doi: 10.1016/j.yexcr.2009.03.021.
16. Matschurat S., Knies U.E., Person V., Fink L., Stoelcker B., Ebenebe C., Behrensdorf H.A., Schaper J., Clauss M. Regulation of EMAP II by hypoxia. Am J Pathol. 2003 Jan; 162(1):93-103. doi: 10.1016/S0002-9440(10)63801-1.
17. Lee D.D., Hochstetler A., Murphy C., Lowe C.W., Schwarz M.A. A distinct transcriptional profile in response to endothelial monocyte activating polypeptide

II is partially mediated by JAK-STAT3 in murine macrophages. Am J Physiol Cell Physiol. 2019 Sep 1; 317(3):C449-C456. doi: 10.1152/ajpcell.00277.2018.
18. Eshaq R.S., Aldalati A.M.Z., Alexander J.S., Harris N.R. Diabetic retinopathy: Breaking the barrier. Pathophysiology. 2017; 24(4):229-41. doi: 10.1016/j.pathophys.2017.07.001.
19. Gupta A., Bhatnagar S. Vasoregression: A shared vascular pathology underlying macrovascular and microvascular pathologies? OMICS. 2015 Dec; 19(12):733-53. doi: 10.1089/omi.2015.0128.
20. Balashevich L.I. & Izmailov A.S. [Diabetic ophthalmopathy]. S-Pb.: Man, 2012. 396 p. [in Russian]. Available on: http://ophthalmobook.com.ua/knigi/oftalmologiya/diagnostika/diabeticheskaya-oftalmopatiya.html
21. Xu J., Chen L.J., Yu J., Wang H.J., Zhang F., Liu Q., Wu J. Involvement of advanced glycation end products in the pathogenesis of diabetic retinopathy. Cell Physiol Biochem. 2018; 48(2):705-717. doi: 10.1159/000491897.
22. van Horssen R., Rens J.A., Schipper D., Eggermont A.M., ten Hagen TL. EMAP-II facilitates TNF-R1 apoptotic signalling in endothelial cells and induces TRADD mobilization. Apoptosis. 2006 Dec; 11(12):2137-45. doi: 10.1007/s10495-006-0284-5.
23. Berger A.C., Alexander H.R., Wu P.C., Tang G., Gnant M.F., Mixon A., Turner E.S., Libutti S.K. Tumour necrosis factor receptor I (p55) is upregulated on endothelial cells by exposure to the tumour-derived cytokine endothelial monocyte-activating polypeptide II (EMAP-II). Cytokine. 2000 Jul; 12(7):992-1000. doi: 10.1006/cyto.2000.0687.
24. Adly A.A.M., Ismail E.A., Tawfik L.M., Ebeid F.S.E, Hassan A.A.S.. Endothelial monocyte activating polypeptide II in children and adolescents with type 1 diabetes mellitus: Relation to micro-vascular complications. Cytokine. 2015 Dec; 76(2):156-162. doi: 10.1016/j.cyto.2015.06.006.
25. Mohyl'nyts'ka L.A. Serum levels of endothelial monocyte-activating polypeptide-II in type 2 diabetes mellitus. Fiziol. Zh. 2014; 60(1): 84-90. doi: https://doi.org/10.15407/fz60.01.084.

Conflicts of interest: authors have no conflict of interest to declare.
Received: 20.11.2020
Revised: 15.12.2020
Accepted: 22.12.2020

ЗВ'ЯЗОК З ПРОГРЕСІЄЮ ДІАБЕТИЧНОЇ НЕПРОЛІФЕРАТИВНОЇ РЕТИНОПАТІЇ ПРИ ЦУКРОВОМУ ДІАБЕТІ 2-го ТИПУ ВМІСТУ У КРОВІ ЕНДОТЕЛІАЛЬНОГО МОНОЦИТАКТИВУЮЧОГО ПОЛІПЕПТИДУ-II

[1]Риков С.О., [1]Коробов К.В., [1]Могілевський С.Ю., [2]Зябліцев Д.С.

[1]Національна медична академія післядипломної освіти імені П.Л. Шупика, Київ, Україна
[2]Національний медичний університет імені О.О. Богомольця, Київ, Україна
denis898@ukr.net

Актуальність. Чисельні прозапальні та антиангіогенні властивості ендотеліального моноцитактивуючого поліпептиду-II (EMAP-II)I дозволяють припустити його можливу роль у виникненні та прогресуванні діабетичної непроліферативної ретинопатії (ДНПР) при цукровому діабеті 2 типу (ЦД2).

Мета: визначити вміст у крові пацієнтів на ЦД2 EMAP-II та встановити його зв'язок з прогресією ДНПР.

Матеріали та методи. Було обстежено 91 пацієнта з ЦД2Т (182 ока), яких розподілили на групи: 1 (n=66) – ДНПР не було на обох очах і 2 (n=25) – у яких на одному оці діабетичних змін не було, а на іншому були відмічені поодинокі судинні аномалії (рівень ETDRS 14, 15). До контрольної групи було залучено 25 осіб відповідного віку та статі. Повторно пацієнтів обстежували через 1 рік. Вміст EMAP-II визначали імуноферментним методом у плазмі крові одноразово на початку дослідження. Для статистичних досліджень використано статпакети MedStat і MedCalc v.15.1 (MedCalc Software bvba).

Результати. Аналіз клініко-лабораторних показників показав, що початкові прояви діабетичного ураження сітківки проявлялися у 27,5% пацієнтів через 7,16±1,11 років, та супроводжувалися більшою глікемією. Вміст EMAP-II при ЦД2 був багаторазово збільшеним у порівнянні з контролем, що залежало від наявності діабетичних судинних змін сітківки: у пацієнтів без змін сітківки (1 група) – у 3,7 рази, а у пацієнтів з поодинокими судинними аномаліями сітківки (2 група) – у 5,2 рази ($p<0,001$). Вміст EMAP-II на початку дослідження був пов'язаний з прогресію діабетичних змін сітківки через 1 рік – за їх наявністю він був у 1,5 рази більшим, ніж без таких ($p<0,001$). Стратифікація за стадією ДНПР через 1 рік також показала залежність вираженості діабетичних змін сітківки від початкового вмісту EMAP-II: при наявності поодиноких судинних аномалій та початковій ДНПР він був збільшений у 3-4 рази, тоді як при помірній ДНПР – у 5,9 рази ($p<0,001$ для всіх порівнянь).

Висновок. Встановлено суттєве збільшення вмісту EMAP-II при ЦД2 та залежність початкових діабетичних змін сітківки та ступеню їх прогресії через 1 рік від приросту вмісту EMAP-II у крові.

Ключові слова: діабетична непроліферативна ретинопатія, цукровий діабет 2 типу, EMAP-II

СВЯЗЬ ПРОГРЕССИИ ДИАБЕТИЧЕСКОЙ НЕПРОЛИФЕРАТИВНОЙ РЕТИНОПАТИИ ПРИ САХАРНОМ ДИАБЕТЕ 2-ГО ТИПА С СОДЕРЖАНИЯ В КРОВИ ЭНДОТЕЛИАЛЬНОГО МОНОЦИТАКТИВИРУЮЩЕГО ПОЛИПЕПТИДА-II

[1]Рыков С.О., [1]Коробов К.В., [1]Могилевский С.Ю., [2]Зяблицев Д.С.

[1]Национальная медицинская академия последипломного образования имени П.Л. Шупика, Киев, Украина
[2]Национальний медицинский университет имени А.А. Богомольца, Киев, Украина
denis898@ukr.net

Актуальность. Многочисленные провоспалительные и антиангиогенные свойства эндотелиального моноцитактивирующего полипептида-II (EMAP-II) позволяют предположить его возможную роль в возникновении и прогрессировании диабетической непролиферативной ретинопатии (ДНПР) при сахарном диабете 2 типа (СД2Т).

Цель – определить содержание в крови пациентов с СД2Т EMAP-II и установить его связь с прогрессией ДНПР.

Материалы и методы. Обследован 91 пациент с СД2Т (182 глаза), которых распределили на группы: 1 (n=66) – ДНПР не было на обоих глазах, и 2 (n=25) – на одном глазу диабетических изменений не было, а на другом были отмечены единичные сосудистые аномалии (уровень ETDRS 14, 15). В контрольную группу вошли 25 пациентов соответствующего возраста и пола. Повторно пациентов обследовали через 1 год. Содержание EMAP-II определяли иммуноферментным методом в плазме крови однократно в начале исследования. Для статистических исследований использованы статпакеты MedStat и MedCalc v.15.1 (MedCalc Software bvba).

Результаты. Анализ клинико-лабораторных показателей показал, что начальные проявления диабетического поражения сетчатки проявлялись у 27,5% пациентов через 7,16±1,11 лет и сопровождались большей гликемией. Содержание EMAP-II при СД2 был многократно увеличенным по сравнению с контролем, что зависело от наличия диабетических сосудистых изменений сетчатки: у пациентов без изменений сетчатки (1 группа) – в 3,7 раза, а у пациентов с начальными сосудистыми аномалиями (2 группа) – в 5,2 раза ($p<0,001$). Содержание EMAP-II в начале исследования было связано с прогрессией диабетических изменений сетчатки через 1 год – при их наличии оно было в 1,5 раза больше, чем без таковых ($p<0,001$). Стратификация по стадии ДНПР через 1 год также показала зависимость выраженности диабетических изменений сетчатки от начального содержания EMAP-II: при наличии единичных сосудистых аномалий и начальной ДНПР он был увеличен в 3-4 раза, тогда как при умеренной ДНПР – в 5,9 раза ($p<0,001$ для всех сравнений).

Вывод. Установлено существенное увеличение содержания EMAP-II при СД2 и зависимость начальных диабетических изменений сетчатки и степени их прогрессии через 1 год от прироста содержания EMAP-II в крови.

Ключевые слова: диабетическая непролиферативная ретинопатия, сахарный диабет 2 типа, EMAP-II

DOI: https://doi.org/10.32345/2664-4738.4.2020.04
UDC: 617.764.6-002-089

COMPLICATIONS IN SURGICAL TREATMENT OF PATIENTS WITH CHRONIC DACRYOCYSTITIS

Minaiev O.O. (https://orcid.org/0000-0003-3652-0887)

Donetsk National Medical University, Lyman, Ukraine
dr.min.alex@gmail.com

Relevance. Effective treatment of chronic dacryocystitis (CD) remains an urgent problem of modern ophthalmology and rhinology. When studying this issue, not enough attention is always paid to complications.

Objective – to analyze the existing complications in the surgical treatment of patients with CD.

Material and methods. The study group (1st group) consisted of 45 patients with CD, who underwent endonasal endoscopic dacryocystorhinostomy (EEDCR) according to the developed own method, the comparison group (2nd group) included 36 patients who after performing the developed EEDCR a polyvinyl chloride (PVC) conductor was installed in the area of the dacryorhinostoma. The control group (3rd group) included 28 patients who underwent EEDCR according to the traditional method: with the preservation and plastic placement of mucous flaps and with the installation of PVC-conductor. Patients of the 1st and 2nd groups were divided into 2 subgroups: 1A and 2A included patients who underwent computed tomography (CT) of the lacrimal ducts in the preoperative period according to the developed method, and patients of subgroups 1B and 2B – according to the traditional algorithm. Statistical analysis was performed using the licensed program MedCalc (MedCalc Software bvba, Ostend, Belgium; 2017).

Results. In patients of subgroups 2A, 2B and group 3 in the period of 1.5 months after surgery, local complications of the eyeball were recorded: epiphora during implant wearing, severe conjunctivitis, prolapse and displacement of the implant, granulation in the lower lacrimal duct, ectopia of the lower lacrimal point. No such complications were observed in patients of subgroups 1A and 1B. In patients of subgroups 1B, 2B and group 3 in the early postoperative period were recorded varying degrees of swelling of the lower eyelid, as well as nosebleeds after removal of tampons. No such complications were observed in patients of subgroups 1A and 2A, and the difference between the groups was statistically significant ($p < 0.05$).

Conclusion. CT of the lacrimal ducts and EEDCR according to the developed methods are effective and allow their combined use to avoid local complications from the nasal cavity and eyeball.

Keywords: Chronic dacryocystitis, endonasal dacryocystorhinostomy, complications.

Relevance. Despite significant advances in science and technology, effective treatment of chronic dacryocystitis (CD) remains an urgent problem of modern ophthalmology and rhinology. There are external, endonasal and transcanalicular access to the lacrimal sac, each with a considerable number of modifications. However, as is known, endonasal dacryocystorhinostomy has a number of undeniable advantages: no cosmetic defect,anatomical features and anomalies of intranasal structures with a possibility of their simultaneous correction are considered, relatively short duration of operation, short postoperative rehabilitation period [1-4].

When performing various modifications of endonasal endoscopic dacryocystorhinostomy (EEDCR) the use of lacrimal implants remains ambiguous: there are many proponents of intubation of the lacrimal duct (LD) [5-7], as well as its opponents [8-12]. Opposing views among scientists on storage and plastic stacking [13-15] or delete [16-18] mucous flaps of the lateral wall of the nasal cavity and the medial wall of the lacrimal sac.

In studying the effectiveness of surgical restoration of tearing, the authors examine many indicators and factors, but due to the lack of a standardized approach in assessing treatment outcomes, such indicators, as a complication, not enough attention is always paid [19].

Objective: analyze the existing complications in the surgical treatment of patients with CD.

MATERIALS AND METHODS

The study included 109 patients with chronic dacryocystitis, which were examined and operated in the period 2004-2014 years on the bases of the Department of Otorhinolaryngology, Faculty of Internship and Postgraduate Education, Donetsk National Medical University, Ministry of Health of Ukraine. Of these, 86 women and 23 men aged 18 to 78 years (on the average, 49,1±16,2 years). The duration of complaints of tearing ranged from 2 months to 9 years. In all patients, chronic dacryocystitis was in remission. In all patients, tearing resumed after EEDCR.

Depending on the modification in which the EEDCR was performed, all patients were divided into 3 groups. In 1 group (Study) consisted of 45 patients to whom EEDCR were performed according to the method developed by us. In 2 (Comparison group) 36 patients were included, who after performing our EEDCR in the area of dacryorhinostoma installed a conductor made of polyvinyl chloride (PVC). The 3rd (Control) group included 28 patients who underwent EEDCR according to the generally accepted method: with preservation and

plastic laying of the cut flaps of the mucous membrane of the nasal cavity and lacrimal sac and with the installation of PVC conductor – archival material.

Developed way EEDCR («Method for endonasal endoscopic surgical treatment of chronic suppurative dacryocystitis», Ukrainian patent for the model № 53616 from 11.10.2010 year, bulletin № 19/2010) was as follows: at the stage of excision of the U-shaped flap of the mucous membrane of the nasal cavity first performed the identification of the incision site by diaphanoscopy, at the stage of opening the lacrimal sac, the latter was cut to the bottom (maximum down), and the excised flaps of the lateral wall of the nasal cavity and the medial wall of the lacrimal sac were excised [20]. Such differences allow to avoid stagnation and suppuration of a tear, to carry out its passage uniform and unobstructed, thus, helping to minimize the process of scarring (formation of stricture) in the area of dacryorhinostoma.

Depending on the computed tomography (CT) option LD, patients of groups 1 and 2 were divided into 2 subgroups (Table 1). Subgroups 1A and 2A included patients who underwent contrast-enhanced CT LD in the preoperative examination according to the method developed by us. Subgroups 1B and 2B consisted of patients who underwent CT LD according to the traditional algorithm. In turn, patients of the control clinical group underwent dacryocystography in the preoperative examination, and to clarify the condition of the intranasal structures – computed tomography of paranasal sinuses.

A method of performing CT LD with contrast has been developed («The method of determining the topographic and anatomical relationships of the lacrimal sac with the surrounding structures», Ukrainian patent for the model №66910 from 25.01.2012, bulletin № 2/2012) was as follows: before the study LD washed, removing purulent contents; then a water-soluble contrast agent was injected into the LD lumen (sodium amidotrisoate 60%); then no later than 5 minutes began CT scan in coronary projection with a step of not more than 1 mm from the nasal cavity to the border between the anterior and posterior cells of the lattice labyrinth – the basal plate (area of interest), and then to the wedge-shaped sinus with a step of 5 mm. Performed 3D-reconstruction of images.The obtained data were analyzed according to the developed algorithm [21].

In the early postoperative period, all patients were observed in hospital and on an outpatient basis. After inpatient treatment, patients were examined every 3-4 days for two weeks, then once every 7 days for 2 weeks, then once a month for 5 months and once every six months for 18 months. Tampons were removed from the nasal cavity for 1-2 days after surgery. In patients of 2 and 3 clinical groups, the conductor was removed from the lacrimal ducts after 1.5 months. All patients were treated daily with a gentle toilet of the nasal cavity, instructed on self-care of the nasal cavity. Medical support of patients of all groups was standard and included antibacterial drugs (systemic and local), antihistamines, irrigation therapy (saline solutions, topical steroids).

Patients in the study clinical group at each visit during the first month, the lacrimal ducts were washed with antiseptic solutions. Patients in the control clinical group and the comparison group were recommended to instill solutions of antiseptics for the entire period of the implant in the LD.

To assess the statistical significance of differences between the studied groups when comparing frequencies in independent groups, the Chi-square test ($\chi 2$) and Fisher's exact test were used. Differences were considered statistically significant at a significance level of less than 5% ($p < 0,05$). The data in the tables are given in absolute (abs.) And percentage (%) values. Statistical analysis was performed using a licensed program MedCalc (MedCalc Software bvba, Ostend, Belgium; 2017).

Table 1

Distribution of patients by clinical groups taking into account preoperative CT-examination and performed surgical treatment

№	Clinical group		Surgical treatment	Preoperative examination
1	The study group (S), n=45	A	Endonasal endoscopic dacryocystorhinostomy according to the proposed method	CT of the lacrimal duct with contrast according to the method developed by us
		B		CT of the lacrimal duct with a traditional algorithm
2	Comparison group (Cm), n=36	A	Endonasal endoscopic dacryocystorhinostomy according to the proposed method + implant	CT of the lacrimal duct with contrast according to the method developed by us
		B		CT of the lacrimal duct with a traditional algorithm
3	Control group (Cn), n=28		Endonasal endoscopic dacryocystorhinostomy in the traditional way	–

RESULTS AND DISCUSSION

Intraoperative complications were not observed in any patient. In the postoperative period, the general somatic condition of all patients was satisfied.

Among local complications, nasal bleeding was observed in 7 (6.4%) patients in the early postoperative period. In all these patients, it occurred 24-48 hours after surgery, immediately after removal of tampons. Bleeding was associated with damage to the nasal mucosa during surgery, eliminated by re-tamponade of the nasal cavity in 6 (5.5%) patients or coagulation of blood vessels with a suction coagulator, which was observed in one (0.9%) patient.

In 8 (7.3%) patients the next day after surgery there was swelling of the lower eyelid of varying severity. In all patients, this complication resolved on the background of conservative treatment for several days.

The distribution of local complications (nosebleeds and swelling of the lower eyelid) by clinical groups is shown in Table 2.

As can be seen from the data in table 2, almost the same percentage of nasal bleeding and swelling of the lower eyelid was observed in patients of subgroups 1B, 2B and group 3, and in subgroups 1A and 2A in any case no such complications were observed, the difference between the groups was statistically significant ($p<0,05$). In our opinion, the worst indicators in subgroups 1B, 2B and in group 3 were associated with greater trauma to the structures surrounding the lacrimal sac, when accessing it and finding it. The absence of complications in subgroups 1A and 2A was probably due to the greater informativeness of the obtained CT data in determining the ratio of pathologically altered lacrimal ducts and adjacent intranasal structures, thanks to which there was a clearer direction of surgical intervention and more economical access to a lacrimal sac was carried out.

Local complications of the eyeball in the postoperative period were observed in subgroups 2A, 2B and group 3. In 4 (3,7%) patients developed severe conjunctivitis on the background of being in LD implant for 1.5 months. One patient was from subgroups 2A and 2B, one – group 3 (Table 3). Inflammatory phenomena in all cases were stopped by the appointment of a fixed combination of dexamethasone, neomycin sulfate and polymyxin. Sulfate in the form of eye drops 4 times a day for 7-10 days. No such complications were observed in patients of the studied clinical group.

In three (2.8%) patients there was a loss or displacement of implants in the follow-up period from 2 weeks to 1 month of wearing: these were 2 patients from group 3 and 1 patient from subgroup 2B (Table 3). In all cases, the PVC conductor was reinstalled with endoscopic control.

Two (1.8%) patients from subgroup 2A and group 3 due to prolonged stay in the LD of the implant in the area of the lower lacrimal duct formed granulations. This required additional ophthalmic guidance to remove them.

Epiphora during implant wearing was noted in 12 (11.0%) patients: 6 – from group 3 (3 patients from subgroups 2A and 2B). Tearing in this category of patients persisted until the implants were removed and ranged from 2 to 4 points on a scale P.L. Munk. This was apparently due to the fact that the PVC conductor installed in the lower lacrimal duct prevented the outflow of tears, and the upper lacrimal point and the upper lacrimal duct in the proper volume could not compensate for the tear function.In addition, the implant somewhat filled the lumen of the common lacrimal duct and dacryorhinostoma and, thus, hindered the outflow of tears. Also, as a foreign body in the LD and nasal cavity, it could stimulate tear hyperproduction. In turn, in the control clinical group could prevent the outflow of tears,

Table 2

The incidence of complications of nosebleeds and lower eyelid edema in patients of clinical groups, n=109

Indicator of local complication	1A (n=28)		1B (n=17)		2A (n=21)		2B (n=15)		3 (n=28)	
	abs.	%	abs..	%	abs.	%	abs.	%	abs.	%
Nose bleeding	0	0	2	11,8	0	0	2	13,3	3	10,7
Swelling of the lower eyelid	0	0	2	11,8	0	0	2	13,3	4	14,3

Table 3

Local complications of the eyeball, detected in the postoperative period in patients of clinical groups, n=109

Indicator of local complication	1A (n=28)		1B (n=17)		2A (n=21)		2B (n=15)		3 (n=28)	
	abs.	%	abs.	%	abs.	%	abs.	%	абс.	%
Conjunctivitis is pronounced	0	0	0	0	1	4,8	1	6,7	2	7,1
Granulations in the area of the lower lacrimal duct	0	0	0	0	1	4,8	0	0	1	3,6
Ectopia of the lower lacrimal point	0	0	0	0	0	0	1	6,7	1	3,6
Epiphora during implant wearing	0	0	0	0	3	14,3	3	20	6	21,4
Implant prolapse	0	0	0	0	0	0	1	6,7	2	7,1
Total	0	0	0	0	5	23,8	6	40,0	12	42,9

in addition to the PVC conductor, also swollen displaced flaps of the mucous membrane of the lateral wall of the nasal cavity and the medial wall of the lacrimal sac.

Two (1.8%) patients from subgroup 2B and group 3 had ectopia of the lower lacrimal point. This complication was due to her prolonged stay in the downward position of the conductor. Such patients were observed by an ophthalmologist, and in six months the position of the lacrimal point returned to normal.

Local complications of the eyeball are listed in the Table 3.

Thus, as can be seen from the data in table 3, in patients of subgroups 1A and 1B, who underwent endonasal endoscopic dacryocystorhinostomy without PVC conductor in LD, no complications were observed. At the same time, in patients who underwent major surgery to establish a conductor in LD,observed almost all variants of complications. It should be noted that in group 2A, where in the preoperative period performed CT according to the method developed by us, the least number of ophthalmic complications was noted – 5 (23,8%) observations. At the same time, in patients of subgroup 2B and group 3 complications were recorded in 6 (40,0%) and 12 (42,9%) patients, respectively.

CONCLUSIONS

The developed method of endonasal endoscopic dacryocystorhinostomy meets the principles of cost-effective surgery and is effective in the treatment of patients with chronic dacryocystitis in terms of local complications.

The use of CT of the lacrimal ducts according to the developed method allows to improve the results of surgical treatment in terms of local complications.

The direction of surgery and the absence of a conductor in the tear ducts avoid local complications from the nasal cavity and eyeball.

REFERENCES

1. Magomedov M.M., Borisova O.Yu., Bakharev A.V., Lapchenko A.A., Magomedova N.M., Gadua N.T. [The multidisciplinary approach to the diagnostics and surgical treatment of the lacrimal passages]. Otolarginology bulletin. 2018; 83(3):88-93. [in Russian]. DOI: https://doi.org/10.17116/otorino201883388
2. At'kova E.L., Yartsev V.D., Krakhovetskiy N.N., Reznikova L.V., Root A.O. [Study of the peculiarities of the structure of the nasolacrimal duct orifice according to the data of multislice computed tomography]. Journal of radiology and nuclear medicine. 2018; 99(2):63-70. [in Russian]. DOI: https://doi.org/10.20862/0042-4676-2018-99-2-63-70
3. Kumar S., Mishra A.K., Sethi A., Mallick A., Maggon N., Sharma H., Gupta A. Comparing Outcomes of the Standard Technique of Endoscopic DCR with Its Modifications: A Retrospective Analysis. Otolaryngol Head Neck Surg. 2019 Feb; 160(2):347-54. DOI: https://doi.org/10.1177/0194599818813123
4. Li E.Y., Wong E.S., Wong A.C., Yuen H.K.. Primary vs Secondary Endoscopic Dacryocystorhinostomy for Acute Dacryocystitis With Lacrimal Sac Abscess Formation: A Randomized Clinical Trial. JAMA Ophthalmol. 2017 Dec 01; 135(12):1361-66. DOI: https://doi.org/10.1001/jamaophthalmol.2017.4798
5. Feng Y.F., Cai J.Q., Zhang J.Y., Han X.H. A meta-analysis of primary dacryocystorhinostomy with and without silicone intubation. Can J Ophthalmol. 2011; 46(6):521-7. DOI: https://doi.org/10.1016/j.jcjo.2011.09.008
6. Madge S.N., Selva D. Intubation in routine dacryocystorhinostomy: why we do what we do. Clinical and Experimental Ophthalmology. 2009; 37: 620-3. DOI: https://doi.org/10.1111/j.1442-9071.2009.02094.x
7. Wu S., Xu T., Fan B., Xiao D. Endoscopic dacryocystorhinostomy with an otologic T-type ventilation tube in repeated revision cases. BMC Ophthalmol. 2017; 17(1):138. DOI: https://doi.org/10.1186/s12886-017-0539-7
8. Pakdel F. Silicone Intubation Does not Improve the Success of Dacryocystorhinostomy in Primary Acquired Nasolacrimal Duct Obstruction. Journal of Ophthalmic and Vision Research. 2012; 7 (3):271-2. PMID: 23264872. URL: https://www.ncbi.nlm.nih.gov/pmc/articles/PMC3520599/
9. Ananth L., Hosamani P., Chary G. Efficacy of endonasal dacryocystorhinostomy, using 'cold steel' instruments without stenting, in treatment of distal nasolacrimal duct obstruction. J Laryngol Otol. 2011; 125(6):590-4. DOI: https://doi.org/10.1017/s002221511100017x
10. Chong K.K., Lai F.H., Ho M., Luk A., Wong B.W., Young A. Randomized trial on silicone intubation in endoscopic mechanical dacryocystorhinostomy (SEND) for primary nasolacrimal duct obstruction. Ophthalmology. 2013;120(10):2139-45. DOI: https://doi.org/10.1016/j.ophtha.2013.02.036
11. Smirnov G., Tuomilehto H., Terasvirta M., Nuutinen J, Seppa J. Silicone tubing is not necessary after primary endoscopic dacryocystorhinostomy: a prospective randomized study. American Journal of Rhinology. 2008; 22(2):214-7. DOI: https://doi.org/10.2500/ajr.2006.20.2955
12. Unlu H.H., Gunhan K., Baser E.F., Songu M. Long-term results in endoscopic dacryocystorhinostomy: is intubation really required? Otolaryngology – Head and Neck Surgery. 2009; 140(4):589-95. DOI: https://doi.org/10.1016/j.otohns.2008.12.056
13. Cukurova I., Caner Mercan G., Cetinkaya E., Gumusssoy M, Soken H. Endoscopic dacryocystorhinostomy: outcomes using mucosal flap preserving technique. Eur Arch Otorhinolaryngol. 2013; 270(5):1661-6. DOI: https://doi.org/10.1007/s00405-012-2285-z
14. Mueller S.K., Freitag S.K., Lefebvre D.R., Bleier B.S. Endoscopic DCR using bipedicled interlacing mucosal

flaps. The Laryngoscope. 2017; 128(4):794-7. DOI: https://doi.org/10.1002/lary.26730
15. Peng W., Tan B., Wang Y., Wang H., Wang Z., Liang X. A Modified Preserved Nasal and Lacrimal Flap Technique in Endoscopic Dacryocystorhinostomy. Sci Rep. 2017; 28;7(1):6809. DOI: https://doi.org/10.1038/s41598-017-07364-9
16. Ayoob M., Mahida K. Outcome and complications of endoscopic dacryocystorhinostomy without stenting. Pakistan journal of medical sciences. 2013; 29(5):1236. DOI: https://doi.org/10.12669/pjms.295.3393
17. Saratziotis A., Emanuelli E., Gouveris H., Babighian G. Endoscopic dacryocystorhinostomy for acquired nasolacrimal duct obstruction: creating a window with a drill without use of mucosal flaps. Acta Otolaryngol. 2009; 129(9):992-5. DOI: https://doi.org/10.1080/00016480802495396
18. Wu W., Cannon P.S., Yan W., Tu Y., Selva D., Qu J. Effects of Merogel coverage on wound healing and ostial patency in endonasal endoscopic dacryocystorhinostomy for primary chronic dacryocystitis. Eye (Lond). 2011; 25(6):746-53. DOI: https://doi.org/10.1038/eye.2011.44
19. Green R., Gohil R., Ross P.. Mucosal and lacrimal flaps for endonasal dacryocystorhinostomy: a systematic review. Clin Otolaryngol. 2017; 42(3):514-20. DOI: https://doi.org/10.1177/0194599812447759
20. Dumansky Yu.V., Zabolotny D.I., Boenko S.K., Shlopov V.G., Savchenko O.A., Klimov Z.T., et al. [Functional endoscopic rhinosurgery]. Donetsk:Nord-press; 2010: 202-6. [In Ukrainian]. URL: http://www.irbis-nbuv.gov.ua/cgi-bin/irbis_nbuv/cgiirbis_64.exe?Z21ID=&I21DBN=EC&P21DBN=EC&S21STN=1&S21REF=10&S21FMT=fullwebr&C21COM=S&S21CNR=20&S21P01=0&S21P02=0&S21P03=I=&S21COLORTERMS=1&S21STR=%D0%92%D0%90738296$
21. Zabolotnyi D.I., Minaiev O.O. [Chronic dacryocystitis: Clinical and Radiological parallels]. Scientific Collection «InterConf». Science and practice: implementation to modern society. 2020 Dec; 2(38);913-22. [in Ukrainian] URL: https://interconf.top/documents/2020.12.16-18.pdf

Conflicts of interest: authors have no conflict of interest to declare.
Received: 05.11.2020
Revised: 09.12.2020
Accepted: 22.12.2020

УСКЛАДНЕННЯ ПРИ ХІРУРГІЧНОМУ ЛІКУВАННІ ХВОРИХ З ХРОНІЧНИМ ДАКРІОЦИСТИТОМ

Мінаєв О. О.

Донецький національний медичний університет, Лиман, Україна
dr.min.alex@gmail.com

Актуальність. Ефективне лікування хронічного дакріоциститу (ХД) залишається актуальною проблемою сучасної офтальмології та ринології. При вивченні цього питання не завжди приділяється достатньо уваги ускладненням.

Мета: проаналізувати наявні ускладнення при хірургічному лікуванні хворих з ХД.

Матеріали та методи. Досліджувану групу (1 група) склали 45 пацієнтів з хронічним дакріоциститом, яким ендоназальна ендоскопічна дакріоцисториностомія (ЕЕДЦРС) була здійснена за розробленою власною методикою. У групу порівняння (2 група) було включено 36 хворих, яким після виконання розробленої ЕЕДЦРС в зону дакріориностоми встановлювали провідник з полівінілхлориду (ПВХ). У контрольну групу (3 група) увійшли 28 пацієнтів, яким ЕЕДЦРС виконували за традиційною методикою: зі збереженням і пластичним укладанням слизових клаптів та з установленням ПВХ-провідника. Пацієнти 1 та 2 груп були розділені на 2 підгрупи: до 1А і 2А увійшли пацієнти, яким у передопераційному періоді проводили комп'ютерну томографію (КТ) сльозовідвідних шляхів за розробленою методикою, а хворим підгруп 1В і 2В – за традиційним алгоритмом. Статистичний аналіз проводили за допомогою ліцензованої програми MedCalc (MedCalc Software bvba, Ostend, Belgium; 2017).

Результати. У пацієнтів підгруп 2А, 2В і групи 3 в період 1,5 місяці після операції були зафіксовані місцеві ускладнення з боку очного яблука: епіфора у період носіння імпланта, виражений кон'юнктивіт, випадіння та зміщення імпланта, грануляції у ділянці нижнього слізного канальця, ектопія нижньої слізної точки. Подібних ускладнень у пацієнтів підгруп 1А і 1В не спостерігалось. У пацієнтів підгруп 1В, 2В і групи 3 в ранньому післяопераційному періоді були зафіксовані різного ступеня вираженості набряклість нижньої повіки, а також носові кровотечі після видалення тампонів. У пацієнтів підгруп 1А і 2А такі ускладнення не спостерігались, і відмінність між групами була статистично значущою ($p<0,05$).

Висновок. КТ сльозовідвідних шляхів та ЕЕДЦРС за розробленими методиками є ефективними та дозволяють при їх поєднаному застосуванні уникнути місцевих ускладнень з боку порожнини носа та очного яблука.

Ключові слова: хронічний дакріоцистит, ендоназальна дакріоцисториностомія, ускладнення.

ОСЛОЖНЕНИЯ ПРИ ХИРУРГИЧЕСКОМ ЛЕЧЕНИИ БОЛЬНЫХ С ХРОНИЧЕСКИМ ДАКРИОЦИСТИТОМ

Минаев А.А.

Донецкий национальный медицинский университет, Лиман, Украина
dr.min.alex@gmail.com

Актуальность. Эффективное лечение хронического дакриоцистита (ХД) остается актуальной проблемой современной офтальмологии и ринологии. При изучении этого вопроса не всегда уделяется достаточного внимания осложнениям.

Цель: проанализировать имеющиеся осложнения при хирургическом лечении больных с ХД.

Материалы и методы. Исследуемую группу (1 группа) составили 45 пациентов с ХД, которым эндоназальная эндоскопическая дакриоцисториностомия (ЕЕДЦРС) выполнена по разработанной собственной методике. В группу сравнения (2 группа) были включены 36 больных, которым после выполнения разработанной ЕЕДЦРС в зону дакриориностомы устанавливали проводник из поливинилхлорида (ПВХ). В контрольную группу (3 группа) вошли 28 пациентов, которым ЕЕДЦРС выполняли по традиционной методике: с сохранением и пластической укладкой слизистых лоскутов и с установкой ПВХ-проводника. Пациенты 1 и 2 групп были разделены на 2 подгруппы: в 1А и 2А вошли пациенты, которым в предоперационном периоде проводили компьютерную томографию (КТ) слезоотводящих путей по разработанной методике, а больным подгрупп 1В и 2В – по традиционному алгоритму. Статистический анализ проводили с помощью лицензированной программы MedCalc (MedCalc Software bvba, Ostend, Belgium; 2017).

Результаты. У пациентов подгрупп 2А, 2В и группы 3 в период 1,5 месяца после операции были зафиксированы местные осложнения со стороны глазного яблока: епифора в период ношения импланта, выраженный конъюнктивит, выпадение и смещение импланта, грануляции в области нижнего слезного канальца, эктопия нижней слезной точки. Подобных осложнений у пациентов подгрупп 1А и 1В не наблюдалось. У пациентов подгрупп 1В, 2В и группы 3 в раннем послеоперационном периоде были зафиксированы различной степени выраженности отечность нижнего века, а также носовые кровотечения после удаления тампонов. У пациентов подгрупп 1А и 2А такие осложнения не наблюдались, и различие между группами была статистически значимой ($p < 0,05$).

Выводы. КТ слезоотводящих путей и ЭЭДЦРС по разработанным методикам эффективны и позволяют при их одновременном применении избежать местных осложнений со стороны полости носа и глазного яблока.

Ключевые слова: хронический дакриоцистит, эндоназальная дакриоцисториностомия, осложнения.

DOI: https://doi.org/10.32345/2664-4738.4.2020.05
UDC: 616.724:617.721]-07+616.61/.63:617.721]-07

IRIS CHANGES AT PATIENTS WITH TEMPOROMANDIBULAR JOINT DISEASES AND URINARY SYSTEM PATHOLOGY

Kryzhanivska O.O. (https://orcid.org/0000-0002-1988-0920)

Bogomolets National Medical University, Kyiv, Ukraine
kryzanivska@gmail.com

Relevance. In recent years, many have been devoted to the problem of the temporomandibular joint (TMJ) diseases, in which the attention is paid to the widespread pathology of TMJ at young people, which develops against the background of genetically-determined weakness of connective tissue (CTs), which is also present occurrence of various concomitant diseases of polygenic-multifactorial nature, including the organs of the urinary system (US).

The study of the state of the iris is used as a screening technique that allows you to quickly, simply, harmlessly, informatively, painlessly, non-invasively diagnose the genetically determined structural and functional state and quality of the CTs.

Objective. To investigate the iris changes at patients with TMJ and US diseases, to reveal the dependence of the occurrence of degenerative-dystrophic and destructive-inflammatory changes in the joints and US on the structural and functional state of the CTs, to supplement the known traditional methods of diagnosing genetically determined CTs weakness.

Materials and methods. The study involved 54 patients (men – 14, women – 40), whose average age were 37.3±7.6 years, who were treated at the Dental Medical Center of the Bogomolets NMU. Control group – 22 patients (men – 10, women – 12) without general somatic pathology, with a physiological bite, without signs of TMJ diseases, whose average age was 25.7±6.8 years. Main group – 22 patients (men – 4, women – 28) with TMJ diseases and US pathology, whose average age were 31.6±7.7 years.

Iridobiomicroscopy was performed in patients of both groups. Iridogenetic constitutional signs were determined: color of eyes, constitutional type after E.S. Velkhover, type with the connective tissue weakness after I. Deck, density of iris stoma.

The obtained laboratory data were referenced in the International System of Units and processed by variational statistics using MedStat and EZR v.1.35 (Saitama Medical Center, Jichi Medical University, Saitama, Japan, 2017), which is a graphical interface to RFSC (The R Foundation for Statistical Computing, Vienna, Austria).

Results. Among the examined patients with TMJ diseases and MVS pathology, 75% showed predominantly light eye color and V degree (46.9%) of iris stroma density, in the control group: dark iris color (54.5%) and II degree (68.2%) of iris density.

Iridogenetic constitutional signs of the CT weakness in the patients with TMJ diseases have been determined: light color of eyes, radial-lacunar constitutional type after E.S. Velkhover (75%), lymphatic constitutional type with the connective tissue weakness after I. Deck (57,9%).

Structural local or chromatic changes of the iris stroma in the projection region of the kidney (75%) and bladder (43.6%) in young patients with TMJ diseases showed a congenital weakness of the CTs of these organs and a tendency to develop pathology of the US.

Conclusions. Patients with degenerative-dystrophic and destructive-inflammatory diseases of the TMJ and concomitant US pathology are characterized by iridogenetic constitutional signs of the CTs weakness in the patients with TMJ diseases have been determined: light color of eyes, radial-lacunar constitutional type after E.S. Velkhover, low degree of iris stroma density, lymphatic constitutional type with the connective tissue weakness after I. Deck.

Structural local or chromatic changes of the iris stroma in the projection region of the kidney and bladder in young patients with TMJ diseases showed a congenital weakness of the CTs of these organs and a tendency to develop pathology of the US.

It can be assumed that the development of TMJ diseases in young patients is based on dysplastic changes in the CTs system, which is additionally manifested in the examined patients by pathological changes in the US.

Iridobiomicroscopy, as a screening technique for determining the structural and functional state of CTs, makes it possible to increase the accuracy of diagnostics when examining patients with TMJ diseases who have concomitant pathology of internal organs, including US.

Keywords: temporomandibular joint, connective tissue, kidneys, urinary system, iris, iridobiomicroscopy.

Relevance. The urgency of the problem of diagnosing the state of the temporomandibular joint (TMJ) is due to the high prevalence of joint diseases in persons of different sexes and ages, develops against the background of genetically determined connective tissue (CTs) weakness, which is at the same time the basis for the occurrence of various concomitant diseases of a polygenic multifactorial nature. , including organs of the urinary system (UC) [1-3].

The common origin of the US and the CTs system, a significant number of connective tissue elements involved in its structure, with congenital weakness and inferiority of CTs elements, determine the development of various pathologies of the kidneys and urinary tract [4-6].

The TMJ is built from different types of connective tissue: the ligamentous apparatus and connective tissue capsule, articular cartilage, fibrous disc cartilage, CTs layers between the masticatory muscle bundles, therefore there is a high likelihood of developing TMJ pathology in case of inferiority of connective tissue elements [2, 7, 8].

The use of the method of iridology in dental surgery and maxillofacial surgery is due to the need to consider diseases of the temporomandibular joints in the plane of

organismic multiple organ pathology, which is caused by genetically determined weakness of the connective tissue, pathology of internal organs and body systems; to carry out early diagnosis of concomitant diseases, depending on their iridovisceral manifestations, to predict the long-term possible realization of organ weakness and the course of diseases, to identify a number of dysfunctions and diseases in the preclinical stage of disease development [9].

Iridology is a method for indicating diseases with adaptive trophic changes in the iris of the eye (IE).

It is known that the iris is a unique structure onto which all organs of the human body are projected, and reflects congenital defects associated with the state of connective tissue and are fixed in the genotype by the fourth generation inclusive [2, 10-12]. IE mainly consists of structural elements CTs. Due to their superficial location, the IE connective structure is easily accessible for examination by biomicroscopy.

The folding structure of the iris determines the formation of a large number of various informative signs on it - chromatic or structural local changes in the stroma: enlightenment, pigment and toxic spots, inclusions, rosy fiber, lacunae, rings, radiance, and the like. Evaluation of these changes, taking into account the projection zones of the human body (somatotopic division) into IE, allows with a certain accuracy to establish the location of the pathological focus, taking into account the iridovisceral connection, to carry out nonspecific topical diagnosis of diseases [11, 12].

Iridological studies indicate that the genetically determined state of CTs as a whole reflects the constitutional type, the density of trabecular fibers, and the color of IE as well. [10, 11].

In this regard, iridology is used as a screening technique that allows you to quickly, simply, harmlessly, informatively, painlessly, non-invasively diagnose a genetically determined structural-functional state and quality of CTs in patients with TMJ and US diseases [9].

Objective. To investigate the iris changes at patients with TMJ and US diseases, to reveal the dependence of the occurrence of degenerative-dystrophic and destructive-inflammatory changes in the joints and US on the structural and functional state of the CTs, to supplement the known traditional methods of diagnosing genetically determined CTs weakness.

MATERIALS AND METHODS

The study involved 54 patients (men – 14, women – 40), whose average age was 37.3±7.6 years, who were treated at the Dental Medical Center of the Bogomolets NMU. Control group – 22 patients (men – 10, women – 12) without general somatic pathology, with a physiological bite, without signs of TMJ diseases, whose average age was 25.7±6.8 years. Main group – 22 patients (men – 4, women – 28) with TMJ diseases and US pathology, whose average age were 31.6±7.7 years.

Examination of patients were carried out according to the method of examination of patients with TMJ diseases. Orthopantomography with examination of the heads of the lower jaw, radiography of the TMJ with an open mouth behind Parma, computed tomography (CT) or magnetic resonance imaging (MRI) of the TMJ, iridobiomicroscopy were mandatory.

Iridobiomicroscopy was carried out to diagnose the genetically determined state of CTs of the organism, as evidenced by the structure of the iris of the eye.

IE eyes were examined visually (iridoscopy) with the naked eye and using a magnifying glass with a magnification of 6 times (biomicroscopy), photographed with a Nikon D60 digital camera (iridography), after which the image was stored in a PC database. If necessary, the image was processed using graphic editors and programs GIDRA, ESID-3, Adoble Photoshop CS5 12.0, and ACDSee Pro6 Photo Manager. To establish an iridological diagnosis, patients were examined in the first half of the day between 11 and 13 o'clock, when the pupils have the smallest size, general and local changes in the IE are clearly manifested.

The color of the iris of the eyes (light, dark), the density of trabeculae was determined according to the method of Jensen B. (I-VI degrees) [11], iridogenetic type according to E.S. Velkhover (radial, radially uniform, radially lacunar) [10], iridogenetic constitutional type according to Deck I. (lymphatic, hematogenous, mixed constitution) [10, 11].

The color of the iris of the eye is a genetic trait, inherited by a dominant or recessive route and depends on the number of pigment cells in the stroma. Light-eyed patients have weak protective filters of the iris, which contributes to the development of an imbalance between the protective function of the iris and the regulation of the energy potential of the reticular formation, which is the basis for certain changes in the human body [10-12].

Of great importance for iridodiagnostics is the density of the iris, which is determined by the proximity of the fibers to each other, the fineness of the structures. A clean, dense iris is a sign of a healthy body. The density of the iris structure determines the viability of the body, reflects muscle tone, resistance, the ability to repair various tissues. Iris with dense fibers indicates that a person has good restorative forces, sufficient regenerative potential. Looseness of the fibers indicates low resistance and weak innate regenerative activity. The degree of density of the iris makes it possible to predict the occurrence and course of severe diseases, indicates the genetic characteristics of man [9-12].

The following degrees of density of the iris of the eye have been identified [10]: I, II degrees – a dense stroma, characteristic of people with good health and heredity, strong musculoskeletal system; III degree – trabeculae stretched, weakened, tortuous, which indicates a weak connective tissue of organs and systems of the body. Such people have increased fatigue, low resistance,

predisposition to dysfunctions, which often turn into diseases; IV degree – thinned fibers are tortuous, the gaps between them are elongated, oval in shape. The absence of a homogeneous stroma indicates a low tone of organs and tissues, which indicates poor health, painful response to changes in external and internal factors; V, VI degrees – weak and very weak structure of the connective tissue of the iris. The stroma of the iris of the eye has numerous depressions and cavities that change the color of the iris, dramatically deforming the structure of the circle of the autonomous ring. This structure of the iris indicates the presence of severe hereditary (genetic) [10, 11] and acquired diseases, weak constitution and low body defenses.

Belonging to one of the iridogenetic types also indicates the characteristics of the human body. The radial type, determined by the method of E.S. Velkhover [10], has thin fibers that fit tightly to each other. The radial homogeneous type combines a radial pattern with a dense, homogenously colored ciliary circle. The first and second types are a sign of good constitution and good health. The radial-lacunar type has a thinned, loose connective tissue stroma with scattered depressions – lacunae, which resembles a thin, in places ruptured plate with a chaotic pattern of trabeculae and crypts. This type is inherent in people with a weaker constitution, who often get sick, complain of dysfunction of various organs.

For a more detailed study and a complete reflection of the relationship between the morpho-functional features of the iris and the body as a whole, the iridogenetic constitutional type was determined according to I. Deck [10-12]. Research and taxonomy of iris types was carried out on the basis of analysis of individual areas and the general picture of the iris, taking into account its color and the presence of certain structural signs.

There are the following iridogenetic constitutional types:

1). *Lymphatic constitution*, which includes the following types: *purely lymphatic type* – blue or gray primary color, labile stroma, tortuous, unstable passage of trabeculae in the miliary belt, a clear autonomous ring; *hydrogenoid type*, in which endogenous pathogenic factors were manifested by signs in the form of light flakes and lymphatic rosary (white "pearls" on the periphery of the iris); *type with weakness of CTs* – the presence of a large number of gaps, cracks in the stroma of the iris, atrophy of elastic CTs, its genetically determined weakness; *neurogenic type* – blue or brown eye color, fibrous structure with a clear pattern, straight, stretched iris trabeculae.

2). *Hematogenous constitution* includes *purely hematogenous and latent tetanic types*. Hematogenous constitution is characterized by the presence of brown IE. The latent tetanic type, regardless of color, is characterized by pronounced spastic (adaptation) rings and toxic radiance of the iris.

3). *Mixed constitution (bile type)* – the main layer of IE in most cases has a blue-gray color, and the crypt layer – brown.

In the future, the iris was inspected by topographic zones and sectors. We studied the central part of the iris – the pupil area, which corresponds to the projection of the gastrointestinal tract (GIT), and the ciliary area – the projection of most organs and systems. According to the scheme of projection zones of the human body B. Jensen, the urinary system is projected on the right iris (in hours): bladder and ureters – 4.45-5.00, kidneys – 5.30-5.55 and on the left iris: kidneys – 6.05-6.30, bladder and ureters – 7.0-7.15; and the TMJ sector is located at 10.30-10.45 on the right eye and 1.15-1.30 on the left [9, 11]. The following signs were determined: structural (sinuous, whitish iris fibers, stroma defoliation, lacunae); toxic-dystrophic (lymphatic rosary, toxic radiance, pigmentation); reflex (adaptation rings, protrusion/retraction of the autonomous ring).

The obtained laboratory data were referenced in the International System of Units and processed by variational statistics using MedStat and EZR v.1.35 (Saitama Medical Center, Jichi Medical University, Saitama, Japan, 2017), which is a graphical interface to RFSC (The R Foundation for Statistical Computing, Vienna, Austria). [13].

RESULTS AND DISCUSSION

According to X-ray examination, all patients of the main group (100%) had some degree of structural changes in the TMJ and concomitant pathology of the urinary system, diagnosed by a nephrologist. The surveyed persons of the control group did not have these changes.

The vast majority of patients in the study group were women – 28 people (87.5%), young men with TMJ disease on the background of pathology of the urinary system were less common – 4 (12.5%), which correlates with the literature on the prevalence of this type of disease in patients of different sexes [1, 2].

As a result of the study, patients were diagnosed with pathology of the kidneys and urinary tract: chronic cystitis – 12 (37.5%) cases; oxalate or urate crystalluria – 12 (37.5%); nephroptosis – 3 (9.4%); urolithiasis – 2 (6.3%); chronic pyelonephritis – 2 (6.3%); double kidney – 1 (3.1%).

Patients in the control group, according to anamnestic data, had isolated changes in the urinary system: acute cystitis was found in 1 (4.5%) person, and oxalate crystalluria in 1 (4.5%) of the subjects.

In the analysis of iris in patients of the main group, dark eye color was found in 8 people, light – in 24, which was, respectively, 25% and 75% of the total number of subjects in the group. The degree of density of

trabeculae according to Jensen B.: I – 0, II - 2 (6.25%), III – 2 (6.25%), IV – 11 (34.4%), V – 15 (46.9 %), VI – 3 (9.4%). In the control group, dark iris color was diagnosed in 12 (54.5%) people; light – in 10 (45.6%). The density of iris trabeculae was: I – 5 (22.7%); II – 15 (68.2%); III – 2 (9.1%) people. In the group of persons with pathological changes in the TMJ, the light color of the eyes prevailed, the most common was the V degree of density of the iris. Long thin and tortuous trabeculae formed gaps and indicated a significant weakness of the CTs of the body. The control group was dominated by dark iris color and I and II degrees of iris density, which indicated good health, unencumbered heredity, good regenerative potential.

The existing hereditary predisposition to connective tissue weakness in patients with degenerative-dystrophic and destructive-inflammatory processes in the TMJ and pathology of the urinary system was detected in the determination of iridogenetic constitutional types by Velkhover E.S. Analysis of iridobiomicroscopic examination data showed that the main group of patients was dominated by radial-lacunar type of iris – 24 people, which was 75% of the total number of patients in the group. Radial-type iriss had 5 (15.6%) persons, and radially-homogeneous – 3 (9.4%). The control group had: radial-lacunar type of iris – 5 (22.7%), radial – 12 (54.5%), radially homogeneous – 5 (19.23%).

The obtained values suggest that internal degenerative-dystrophic and destructive-inflammatory changes in the TMJ and pathology of the urinary system were associated with genetically determined weak structural and functional state of the connective tissue of the subjects, which is characteristic of iris with radial-lacunar type of stroma.

Detailed determination of the iridogenetic constitutional type according to Deck I. was carried out on the basis of the analysis of separate sites and the general picture of an iris, taking into account color of an iris and existence of these or those structural signs.

According to the obtained data, in the main group the majority of patients had a lymphatic constitution – 19 (59.4%) persons, hematogenous and mixed constitution were less common – 5 (15.6%) and 8 (25%), respectively. Types of lymphatic constitution were distributed as follows: type with connective tissue weakness – 11 (57.9%), purely lymphatic – 5 (26.3%), hydrogenoid – 2 (10.5%), neurogenic – 1 (5.3%)). Hematogenous constitution had a purely hematogenous type – 3 (60%), latent tetanic – 2 (40%). The mixed constitution was represented by the bile type – 8 (100%).

The distribution of iridogenetic constitutional type in the control group differed: lymphatic constitution was represented by only two types: purely lymphatic – 7 (31.8%) and neurogenic – 2 (9.1%). Hematogenous constitution: 5 (22.7%) of the examined had a purely hematogenous type, 1 (4.6%) had a latent tetanic type, and 7 (31.8%) had a mixed constitution.

Examination of the iris of the eye by topographic areas, sectors, conducted in patients with pathology of the TMJ and urinary system, showed that the projection of the kidneys and urinary system had the following changes: gaps, deflection and tortuosity of stroma fibers, protrusion of the autonomic ring, pigment spots, toxin`s and lymphatic rosary. The examination took into account the structural and toxic-dystrophic signs that appeared on at least one of the irises [2]. These changes in the projection of the kidneys were in 24 (75%) patients, and changes in the bladder – in 14 (43.6%) people. Manifestations of nephroptosis, abnormalities of kidney development, chronic pyelonephritis, cystitis, crystalluria, which were found in patients with arthropathies of the TMJ, are a marker of genetic weakness of the urinary system.

Patients with crystalluria and urolithiasis were more likely to have brown eyes, a combination of structural signs of the iris (lacunae, fibrous stroma) with chromatic ones (pigment spots, pigment sand). In patients with nephroptosis, reflex (protrusion of the autonomic ring) and structural disorders of the iris stroma in the form of trabecular deposition were predominant. Individuals with chronic cystitis had changes in the projection area of the bladder in the form of tortuosity of the iris trabeculae, stroma fibers, the presence of toxic and lymphatic rosary.

Thus, after a detailed analysis of iridogenetic features of the iris of the eye, analyzing the anamnestic data of patients and features of the condition of the iris of the eye, we can assume that light eye color, radial-lacunar constitutional type according to Velkhover E.S., type with connective tissue weakness according to Deck I., reduced density of the iris stroma (V degree) in the subjects are genetically determined traits that indicate a weak connective tissue system, reduced protective properties of the body, reduced organ tone and are the basis for the development of various dysfunctions and various pathologies, including degenerative dystrophic lesions of the TMJ and diseases of the urinary system.

CONCLUSIONS

1. Patients with degenerative-dystrophic and destructive-inflammatory diseases of the TMJ and concomitant US pathology are characterized by iridogenetic constitutional signs of the CTs weakness in the patients with TMJ diseases have been determined: light color of eyes (75%), radial-lacunar constitutional type after E.S. Velkhover (75%), lymphatic constitutional (59.4%), type with the connective tissue weakness after I. Deck (57.9), low of iris stroma density (V degree – 46.9%).

2. Detected structural local or chromatic changes of the iris stroma in the projection of the kidneys (75%) and bladder (43.6%) in patients of the main group indicated a congenital weakness of CT of these organs and a tendency to develop pathology of the urinary system.

3. Based on the results of our studies, we can assume that the development of TMJ in young patients is based

on dysplastic changes in the CTs system, which are additionally manifested in the examined patients by pathological changes in the urinary system.

4. Iridobiomicroscopy, as a screening technique for determining the structural and functional state of CTs, makes it possible to increase the accuracy of diagnostics when examining patients with TMJ diseases who have concomitant pathology of internal organs, including US.

Sources of funding. This article has not received financial support from a government, community, or commercial organization.

REFERENCES

1. De Rossi S.S., Greenberg M.S., Liu F., Steinkeler A. Temporomandibular disorders: evaluation and management. *Med Clin North Am*. 2014 Nov; 98(6): 1353-84. DOI: https://doi.org/10.1016/j.mcna.2014.08.009.
2. Volovar O.S. [Diagnosis and treatment of diseases of the temporomandibular joint on the background of somatic diseases]. Extended abstract of Doctor's thesis. Kyiv 2013; NMU [in Ukrainian] URL: http://irbis-nbuv.gov.ua/cgi-bin/irbis_nbuv/cgiirbis_64.exe?&I21DBN=EC&P21DBN=EC&S21STN=1&S21REF=10&S21FMT=fullwebr&C21COM=S&S21CNR=20&S21P01=0&S21P02=0&S21P03=I=&S21COLORTERMS=0&S21STR=%D0%A0%D0%90402871
3. Luther F., Layton S., McDonald F. Orthodontics for treating temporomandibular joint (TMJ) disorders. *Cochrane Database Syst Rev*. 2016 Jan 7; (1): CD006541. DOI: https://doi.org/10.1002/14651858.cd006541.pub3.
4. Bebeshko V.G., Bruslova K.M., Volodina T.T., Lyashenko L.O., Tsvetkova N.M., Trychlib I.V., **Chernysh T.O., Boyarskiy V.G., Gonchar L.O., Kavardakova N.V.** [Features of clinical symptoms and signs, hematological and biochemical parameters in children with joint hypermobility in a late period upon the chornobyl npp accident]. *Probl Radiac Med Radiobiol*. 2019 Dec; 24: 322-34. [Article in En, Ukrainian]. PMID: **31841477.** DOI: https://doi.org/10.33145/2304-8336-2019-24-322-334.
5. Kalayeva G.Yu., Khokhlova O.I., Deev I.A., Mikheenko G.A. [Risk factors associated with the development of undifferentiated connective tissue dysplasia]. *Bulletin of Siberian Medicine.* 2018; 17(2): 41-8. [in Russian]. DOI: https://doi.org/10.20538/1682-0363-2018-2-41-48.
6. Mambetova A.M., Shabalova N.N., Kravtsova A.A., Indarokov T.R. [Renin-aldosterone system reaction peculiarities in children with urinary organs congenital developmental anomalies combined with varying severity connecting tissue dysplasia syndrome]. *Pediatr*. 2012; 3(2): 30-6. [in Russian]. URL: https://cyberleninka.ru/article/n/osobennosti-reaktsii-renin-aldosteronovoy-sistemy-u-detey-s-vrozhdennymi-porokami-razvitiya-organov-mochevoy-sistemy-na-fone-sindroma/viewer.
7. Kravchenko A.I. [Undifferentiated dysplasia of the connective tissue of the musculoskeletal system (diagnosis, treatment)]. *Trauma*. 2014;15(1):118-24. [in Russian]. URL: https://cyberleninka.ru/article/n/nedifferentsirovannaya-displaziya-soedinitelnoy-tkani-oporno-dvigatelnoy-sistemy-diagnostika-lechenie/viewer.
8. Kadurina T.I., Abbakumova L.N. [Connective tissue dysplasia: way to diagnosis]. *Bulletin of the Ivanovo Medical Academy.* 2014; 19 (3); 5-11. [in Russian]. URL: https://cyberleninka.ru/article/n/displaziya-soedinitelnoy-tkani-put-k-diagnozu/viewer
9. Volovar O.S., Malanchuk V.O., Tsilenko O.L., Kryzhanivska O.O. [Iridodiagnostics in Maxillofacial Surgery]. *Dentistry news*. 2010; 4: 25-30. [in Ukrainian]. URL: https://www.elibrary.ru/item.asp?id=22704139
10. Velhover E.S. [Clinical iridology]. Moscow: Orbita, 1992. 423 p. [in Russian]. URL: https://www.avito.ru/moskva/knigi_i_zhurnaly/klinicheskaya_iridologiya._velhover_e._s.novaya_853473547
11. Ernst E. Iridology: a systematic review. *Forsch Komplementarmed*. 1999 Feb; 6(1):7-9. PMID: 10213874. DOI: https://doi.org/10.1159/000021201.
12. Potebnya G.P., Lisovenko G.S., Krivenko V.V. [Clinical and experimental iridology]. Kyiv: Naukova dumka, 1995. 262 p. [in Russian]. URL: http://www.library.univ.kiev.ua/ukr/elcat/new/detail.php3?doc_id=1037232
13. Hur'yanov V.H., Lyakh Yu.Ye., Pariy V.D., Korotkyy O.V., Chalyy O.V. Biostatistics Guide. Analysis of medical research results in the EZR (R-statistics) package: textbook. Kyiv. 2018; 207. [in Ukrainian]. URL: https://www.researchgate.net/profile/Yaroslav_Tsekhmister/publication/326271449_Posibnik_z_biostatistiki_analiz_rezultativ_medicnih_doslidzen_u_paketi_EZR_R-STATISTICS/links/5b436d09aca2728a0d664341/Posibnik-z-biostatistiki-analiz-rezultativ-medicnih-doslidzen-u-paketi-EZR-R-STATISTICS.pdf

Conflicts of interest: authors have no conflict of interest to declare.
Received: 25.11.2020
Revised: 11.12.2020
Accepted: 22.12.2020

ЗМІНИ ІРИСА У ПАЦІЄНТІВ ІЗ ЗАХВОРЮВАННЯМИ СКРОНЕВО-НИЖНЬОЩЕЛЕПНОГО СУГЛОБА ТА ПАТОЛОГІЄЮ ОРГАНІВ СЕЧОВИДІЛЬНОЇ СИСТЕМИ

Крижанівська О.О.

Національний медичний університет імені О. О. Богомольця, Київ, Україна
kryzanivska@gmail.com

Актуальність. За останні роки проблемі захворювань скронево-нижньощелепного суглоба (СНЩС) присвячено багато епідеміологічних робіт, у яких звернено увагу на широку поширеність патології СНЩС у осіб молодого віку, що розвивається на фоні генетично-детермінованої слабкості сполучної тканини (СТ), що є водночас підґрунтям для виникнення різноманітних супутніх захворювань полігенно-мультифакторної природи, в тому числі органів сечовидільної системи (СВС).

Дослідження стану ірису ока використовують як скринінг-методику, що дозволяє швидко, просто, нешкідливо, інформативно, безболісно, неінвазивно діагностувати генетично обумовлений структурно-функціональний стан та якість СТ організму.

Мета. Вивчити стан ірису ока у пацієнтів із захворюваннями СНЩС і СВС, виявити залежність виникнення дегенеративно-дистрофічних і деструктивно-запальних змін у суглобах та СВС від структурно-функціонального стану СТ організму, доповнити відомі традиційні способи діагностики генетично-схильної слабкості СТ.

Матеріали та методи. Проведено обстеження 54 пацієнтів (чоловіків – 14, жінок – 40), середній вік яких становив 37,3±7,6 років, що перебували на консультації та лікуванні в стоматологічному медичному центрі НМУ імені О.О. Богомольця. Контрольна група склала 22 особи (чоловіків – 10, жінок – 12) без загальносоматичної патології, з фізіологічним прикусом, без ознак ураження СНЩС, середній вік яких склав 25,7±6,8 років. До основної групи увійшло 32 пацієнти (чоловіків – 4, жінок – 28) із захворюваннями СНЩС, середній вік яких становив 31,6 ± 7,7 років, із дегенеративно-дистрофічними захворюваннями СНЩС і супутньою патологією СВС.

Проводили іридобіомікроскопію у пацієнтів обох груп. Визначали колір райдужної оболонки (РО) ока (світлий, темний), щільність розташування трабекул за методикою Jensen B., іридогенетичний тип за Вельховером Е.С., іридогенетичний конституціональний тип за Deck I.

Отримані дані лабораторних досліджень наводили в Міжнародній системі одиниць та обробляли методами варіаційної статистики з використанням пакету MedStat та статистичного пакету EZR v.1.35 (Saitama Medical Center, Jichi Medical University, Saitama, Japan, 2017).

Результати. Серед обстежених пацієнтів із захворюваннями СНЩС і патологією СВС у 75% виявлено переважно світлий колір очей та V ступінь (46,9%) щільності строми ириса, в контрольній групі – темний колір ірису (54,5%) та II ступінь (68,2%) щільності РО.

Для пацієнтів із дегенеративно-дистрофічними та деструктивно-запальними змінами в СНЩС був характерний радіально-лакунарний конституційний тип за Вельховер Е.С. (75%), лімфатична конституція (59,4%), тип зі слабкістю СТ за Deck I (57,9%).

Виявлені структурні локальні чи хроматичні зміни строми райдужної оболонки ока в проекційній ділянці нирок (75 %) і сечового міхура (43,6 %) у пацієнтів молодого віку із захворюваннями СНЩС свідчили про наявну вроджену слабкість СТ зазначених органів та схильність до розвитку патології СВС.

Висновки. Для пацієнтів із дегенеративно-дистрофічними та деструктивно-запальними захворюваннями СНЩС і супутньою патологією СВС характерні іридогенетичні конституційні ознаки слабкості СТ: світлий колір очей, радіально-лакунарний конституційний тип за Вельховер Е.С., лімфатична конституція, тип зі слабкістю СТ за Deck I., низька щільність строми ириса.

Виявлені структурні локальні чи хроматичні змін строми РО ока в проекційній ділянці нирок і сечового міхура у пацієнтів основної групи свідчили про наявну вроджену слабкість СТ зазначених органів та схильність до розвитку патології СВС.

Можна припустити, що в основі розвитку захворювань СНЩС у пацієнтів молодого віку лежать диспластичні зміни в системі СТ, які додатково проявляються у обстежених пацієнтів патологічними змінами СВС.

Проведення іридобіомікроскопії, як скринінг-методики визначення структурно-функціонального стану СТ, дозволяє підвищити точність діагностики при обстеженні пацієнтів із захворюваннями СНЩС, які мають супутню патологію внутрішніх органів, у тому числі захворювання СВС.

Ключові слова: скронево-нижньощелепний суглоб, сполучна тканина, нирки, сечовидільна система, райдужна оболонка ока, іридобіомікроскопія.

ИЗМЕНЕНИЯ ИРИСА У ПАЦИЕНТОВ С ЗАБОЛЕВАНИЯМИ ВИСОЧНО-НИЖНЕЧЕЛЮСТНОГО СУСТАВА И ПАТОЛОГИЕЙ ОРГАНОВ МОЧЕВЫДЕЛИТЕЛЬНОЙ СИСТЕМЫ

Крыжановская О.А.

Национальный медицинский университет имени А.А. Богомольца, Киев, Украина
kryzanivska@gmail.com

Актуальность. За последние годы проблеме заболеваний височно-нижнечелюстного сустава (ВНЧС) посвящено много эпидемиологических работ, в которых обращено внимание на широкую распространенность патологии ВНЧС у лиц молодого возраста, которая развивается на фоне генетически детерминированной слабости соединительной ткани (СТ), что является одновременно основой для возникновения различных сопутствующих заболеваний полигенно-мультифакторной природы, в том числе органов мочевыделительной системы (МВС).

Исследование состояния ириса глаза используют как скрининг-методику, позволяющую быстро, просто, безвредно, информативно, безболезненно, неинвазивно диагностировать генетически детерминированное структурно-функциональное состояние и качество СТ организма.

Цель. Изучить состояние ириса глаза у пациентов с заболеваниями ВНЧС и МВС, выявить зависимость возникновения дегенеративно-дистрофических и деструктивно-воспалительных изменений в суставах и МВС от структурно-функционального состояния СТ организма, дополнить известные традиционные способы диагностики генетически детерминированной слабости СТ.

Материалы и методы. Проведено обследование 54 пациентов (мужчин – 14, женщин – 40), средний возраст которых составлял 37,3 ± 7,6 лет, находившихся на консультации и лечении в стоматологическом медицинском центре НМУ имени А.А. Богомольца. Контрольная группа составила 22 человека (мужчин – 10, женщин – 12) без общесоматической патологии, с физиологическим прикусом, без признаков поражения ВНЧС, средний возраст которых составил 25,7 ± 6,8 лет. В основную группу вошло 32 пациента (мужчин – 4, женщин – 28) с заболеваниями ВНЧС, средний возраст которых составил 31,6 ± 7,7 лет, с дегенеративно-дистрофическими заболеваниями ВНЧС и сопутствующей патологией СВС.

Проводили иридобиомикроскопию у пациентов обеих групп. Определяли цвет радужной оболочки (РО) глаза (светлый, темный), плотность расположения трабекул по методике Jensen B., иридогенетический тип по Вельховеру Е.С., иридогенетический конституциональный тип по Deck I.

Полученные данные лабораторных исследований приводили в Международной системе единиц и обрабатывали методами вариационной статистики с использованием пакета MedStat и статистического пакета EZR v.1.35 (Saitama Medical Center, Jichi Medical University, Saitama, Japan, 2017).

Результаты. Среди обследованных пациентов с заболеваниями ВНЧС и патологией МВС у 75% выявлены преимущественно светлый цвет глаз и V степень (46,9%) плотности стромы ириса, в контрольной группе – тёмный цвет ириса (54,5%) и II степень (68,2%) плотности РО.

Для пациентов с дегенеративно-дистрофическими и деструктивно-воспалительными изменениями в ВНЧС был характерен радиально-лакунарный конституциональный тип по Вельховеру Е.С. (75%), лимфатическая конституция (59,4%), тип со слабостью СТ по Deck I. (57,9%).

Выявленные структурные локальные или хроматические изменения стромы радужной оболочки глаза в проекционной зоне почек (75%) и мочевого пузыря (43,6%) у пациентов молодого возраста с заболеваниями ВНЧС свидетельствовали об имеющейся врожденной слабости СТ указанных органов и склонность к развитию патологии МВС.

Выводы. Для пациентов с дегенеративно-дистрофическими и деструктивно-воспалительными заболеваниями ВНЧС и сопутствующей патологией СВС характерны иридогенетические конституциональные признаки слабости СТ: светлый цвет глаз, радиально-лакунарный конституциональный тип по Вельховеру Е.С., лимфатическая конституция, тип со слабостью СТ по Deck I., низкая плотность стромы ириса.

Выявленные структурные локальные или хроматические изменений стромы РО глаза в проекционной зоне почек и мочевого пузыря у пациентов основной группы свидетельствовали об имеющейся врожденной слабости СТ указанных органов и склонности к развитию патологии МВС.

Можно предположить, что в основе развития заболеваний ВНЧС у пациентов молодого возраста лежат диспластические изменения в системе СТ, что дополнительно проявляется у обследованных пациентов патологическими изменениями МВС.

Проведение иридобиомикроскопии, как скрининг-методики определения структурно-функционального состояния СТ, позволяет повысить точность диагностики при обследовании пациентов с заболеваниями ВНЧС, которые имеют сопутствующую патологию внутренних органов, в том числе заболевания МВС.

Ключевые слова: височно-нижнечелюстной сустав, соединительная ткань, почки, мочевыделительная система, радужная оболочка глаза, иридобиомикроскопия.

DOI: https://doi.org/10.32345/2664-4738.4.2020.06
UDC 616.72-002:[614.778:39]

ETHNO-BOTANICAL SURVEY OF PLANTS USED IN A RHEUMATOID ARTHRITIS TREATMENT: A CASE STUDY OF JOS IN NIGERIA

[1]***Tongshuwar G.T.*** (https://orcid.org/0000-0002-8801-8525)
[2]***Ojetunde A.O.*** (https://orcid.org/0000-0001-6189-5109)
[3]***Oyegoke A.F.*** (https://orcid.org/0000-0003-0998-8556)
[4]***Oyegoke T.*** (https://orcid.org/0000-0002-2026-6864)

[1]*Biochemistry Department, Federal University, Dutsin-ma, Nigeria*
[2]*Physiology Department, Ladoke Akintola University of Technology, Ogbomoso, Nigeria*
[3]*Public Health Unit, Salama Infirmary (Hospital& Maternity), Zaria, Nigeria*
[4]*Chemical Engineering Department, Ahmadu Bello University, Zaria, Nigeria*
geoffreytimothytongshuwar@gmail.com

Relevance. Rheumatoid arthritis (RA) is an autoimmune disorder leading to the inflammation of the joints. This inflammation finds expression in the lining of the synovial tissues causing swellings and severe pains and deterioration of the bone in the long run. This disease's exact etiology is not yet to be ascertained; however, there are claims of the interplay of genetic and environmental factors. RA is one of the diseases ravaging the people of Jos in Nigeria, owing to the high cost of orthodox medicine.

Objective. The study was carried out to collect information and find out plants used to treat rheumatoid arthritis in Jos, Nigeria, in addition to the availability of the plant(s).

Materials and methods. An electronic-based questionnaire was used to get information from the respondents.

Result. Eight species of plants were reported to be used. Garlic (Allium sativum), Ginger (Zingiber officinale), Turmeric (Curcuma longa), and Onion (Allium cepa) were the dominant plants reportedly used. The parts of plants used are the plant bulb and stem. They are reported to be prepared by grinding and herbal mixture; chewing and decoction were not popular. Respondents with this information reported their willingness to share with both family and friends.

Conclusion. This study shows the availability of traditional RA treatment and the preservation of verbal form knowledge.

Keywords: Rheumatoid arthritis (RA), Ethno-medicine, Treatment, Medicinal Plants, Jos.

Relevance. Rheumatoid arthritis (RA) is an autoimmune disorder leading to the inflammation of the joints. The word arthritis means joint inflammation. This inflammation finds expression in the lining of the synovial tissues causing swellings and severe pains, and deterioration of the bone in the long run [1]. Smoking and alcohol consumption have been the major risk factors. Other factors, like birth weight and socioeconomic status, increase the chances of susceptibility [2].

Rheumatoid Arthritis has no known cure. So far, the treatment has aimed only to reduce the disease's progression to a great extent and control inflammation and pain. In line with this, synthetic disease-modifying anti-rheumatic drugs (DMARDs) and Corticosteroids have been developed and modified in recent years. While corticosteroids-based drugs help reduce pain, they do not slow the progression of the disease. On the other hand, DMARDs slow the disease process but with adverse side effects [3]. This downside calls for the search for an effective yet safe alternative for treating RA.

Since ancient times, the use of herbal medicine has been in play. This long-practiced art is now the heart of pharmacological interest as it presents little or no side effects and is relatively cost-effective [1]. Previous literature has shown that plants are effective in treating RA [1]. The use of medicinal plants could be said to be as old as man himself. This knowledge is gotten from years of experience and passed down through generations. In her work, Erhenhi A, 2016, reported the knowledge of three medicinal plants used in the treatment of rheumatism in Edo state, Nigeria [4].

Modern synthetic drugs for the treatment of rheumatoid arthritis have proven to have side effects and are expensive. This birthed the shift in paradigm towards ethnomedicine. Despite their safety, the knowledge of these plants and their medicinal importance is depleting; hence, the need to document this knowledge and scientifically validate their medicinal claims. The use of medicinal plants is an age-long practice in Jos, Nigeria, but there is very scarce documentation of the plants used in treating RA in Jos Plateau State, Nigeria.

Objective. This research seeks to find answers to the following questions: what plant(s) are used in treating rheumatoid arthritis? The part of the plant used, method of preparation, and reason for use. How was the knowledge gotten, and if people are willing to transfer this knowledge? To provide answers to those questions stated earlier, this report aimed to gather information on Jos residents' medicinal plants in Nigeria for rheumatoid arthritis treatment using a questionnaire-based research approach.

MATERIALS AND METHODS

Study area

Jos is the Plateau State's administrative capital, the state situated in the middle belt of Nigeria. The city is the largest in the state. The land is blessed with minerals, among which Tin and Columbite stand out. The discovery of these precious minerals led to the influx of ethnic groups and accounted for its heterogeneous culture.

Jos is located about 1,217 meters above sea level. The climate is closer to the temperate than that of the vast majority of her environs. The temperature averages 21-25oC and drop further to about 7-9oC during the harmattan. This state's vegetative zone makes it favorable for herbs, fruits, and shrubs' agricultural practice. These plant products are mostly used as treatments for various diseases.

Study design and population

The study was carried out using a cross-sectional descriptive design. We collected data in the form of a survey. The population was those who are based in Jos or have lived there before relocating. Those who never resided in the state were not part of the population. Both the population suffering from the disease and those not suffering from it were interviewed.

Study sample size

The study involved males and females from below 30 years of age upward. A total of 102 respondents were interviewed.

Data collection

Data was collected online using an android device containing a Google form questionnaire. The questionnaire contained questions that cut across respondents' demography, the plant used for treatment, method, the reason for use, source, and transfer of knowledge.

Ethical Consideration

The purpose of the survey was made known to each respondent. Each respondent was assured of the confidentiality of their information and that it would be used for the sole purpose of research and nothing else. Ethical consent was obtained from each respondent.

RESULTS AND THEIR DISCUSSIONS

Biodata of the respondents

The biodata of respondents is shown in Fig. 2 to 5. The biodata includes sex (Fig. 2), age (Fig. 3), educational background (Fig. 4), and place of residence (Fig. 5).A total number of 102 people of different ages and gender

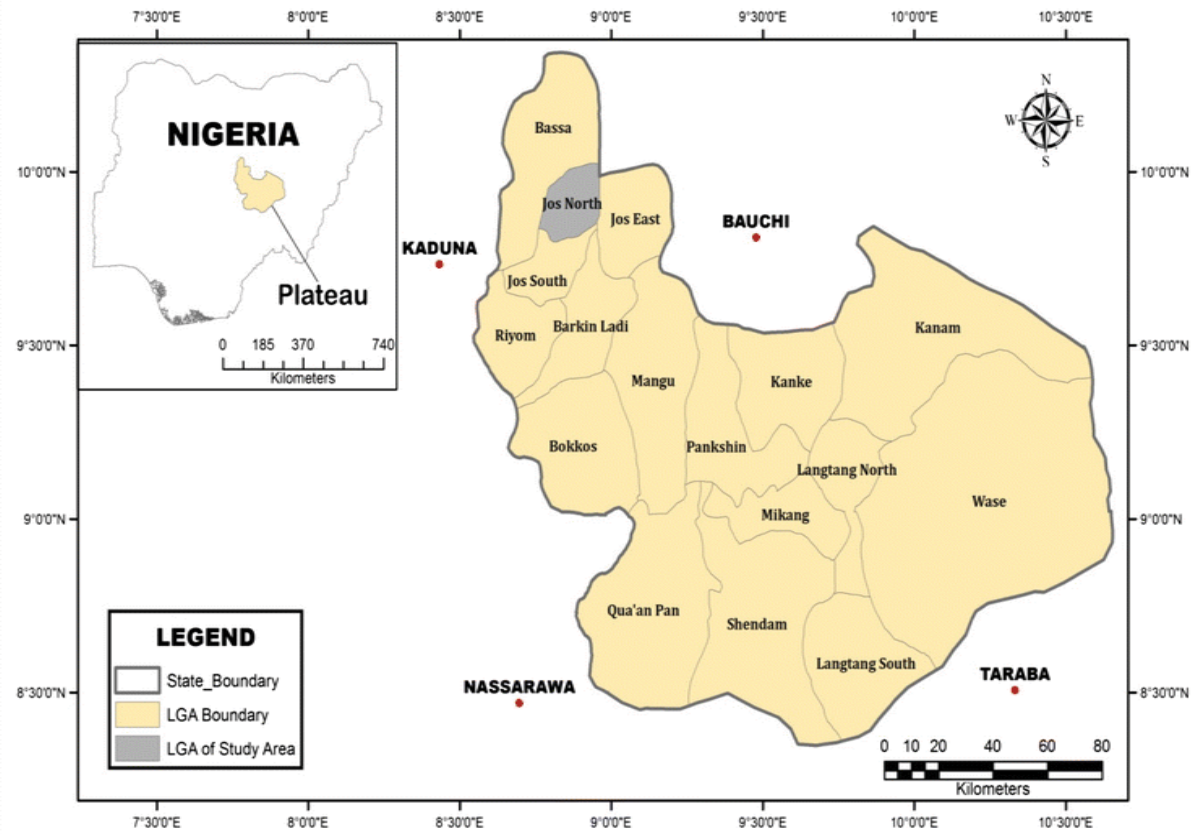

Fig1. Map of Plateau state showing Jos the study area. (Environmental monitoring and assessment)

were interviewed. From the result in Fig. 2, 67.6% of them were females, and 32.4% were males.

From this result, it is seen that most of the respondents were females. Females have been reported to be primarily affected by the disease [5]. This could point to the reason why they are more knowledgeable than males. The vast majority (44.1%) of respondents fall within the age of 30-45 years. This is followed by 30 years and below (25.5%), then 23.5% of the respondents were of the 46-60 years age range. The least was 61-75 years, which constituted 6.9% (Fig. 3).

The respondents with secondary school background were the highest with about 43 respondents, followed by NCE/ND, BSC/BEng/BEdu, primary school, HND-Basic nurse, and MSc/PhD was the least (Fig. 4). In this survey, 95.0% of respondents reside currently in Jos, while 5% once resided in Jos (Fig. 5).

Evaluation of Plant Used by the residences of Jos in the treatment of rheumatoid arthritis disease evaluating its Abundance, Preparation Methods, and Effectiveness

The plants used by the people of Jos in treating RA are shown in Figures 6-10. They are shown in terms of their abundance, method of preparation, and the plant's effectiveness in combating the disease.

A total number of nine (8) different plant species were reported to be used from this survey. They are Garlic, Ginger,Gayan pepper, Turmeric, Jetroper, lemongrass, bitter kola, and onions (Fig. 6). In the order of citation, garlic has a total count of 56, which is the highest, followed by a ginger with a count of 24. Turmeric has a count of 8, while onion(s) has 10 respondents. From this survey, it was observed that garlic and ginger are popular, and the most predominant plants used in the treatment of (RA) in the study area.

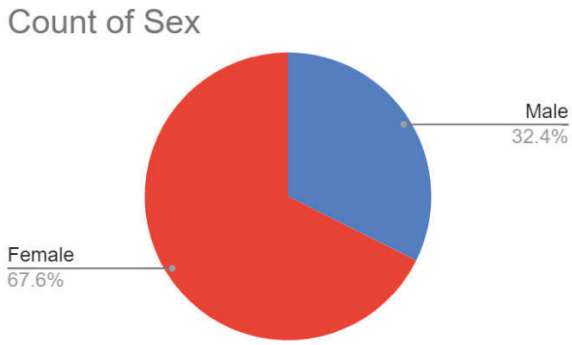

Fig. 2. Sex distribution

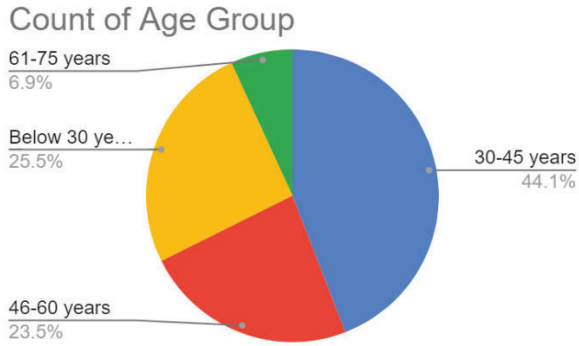

Fig. 3. Age group

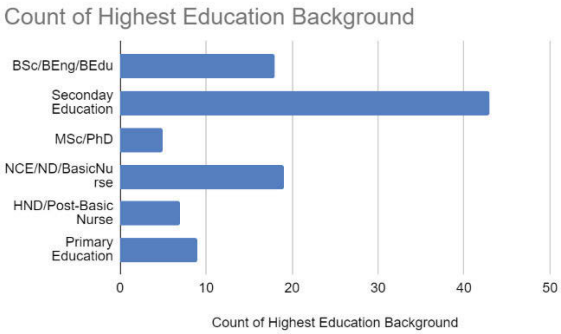

Fig. 4. The highest education background distribution

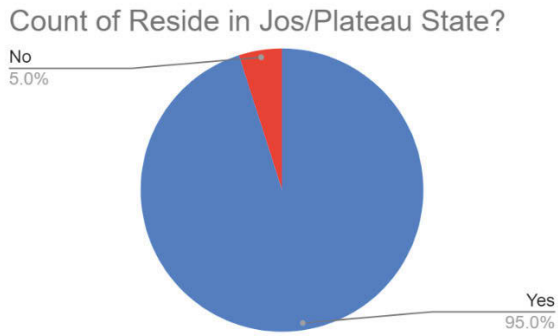

Fig. 5. Respondents' residency

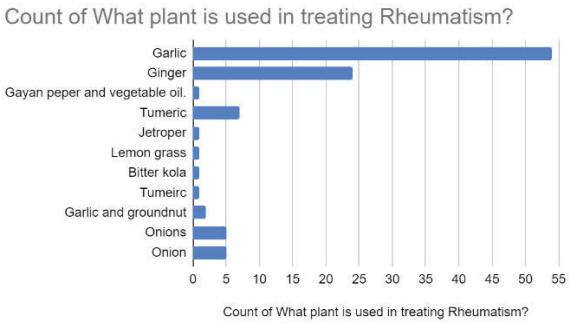

Fig. 6. The plant used in the RA treatment

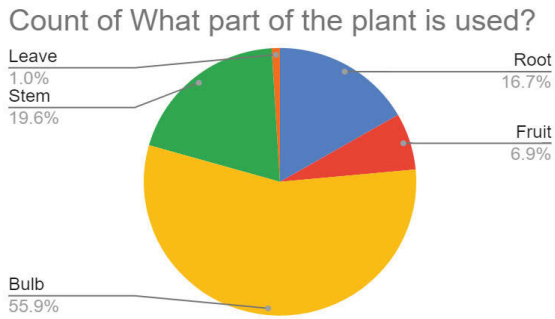

Fig. 7. Plant's part used in the treatment

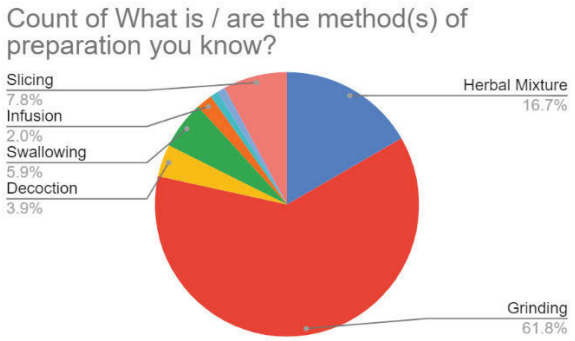

Fig. 8. Survey of preparation method

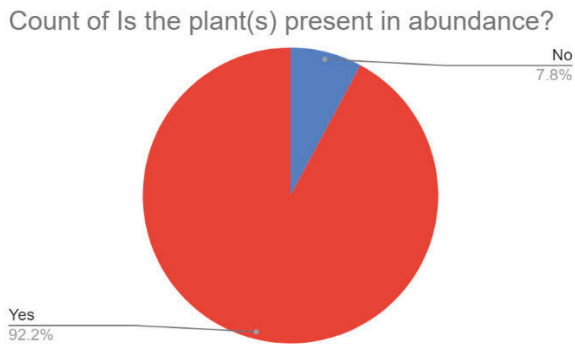

Fig. 9. Plants' abundance survey

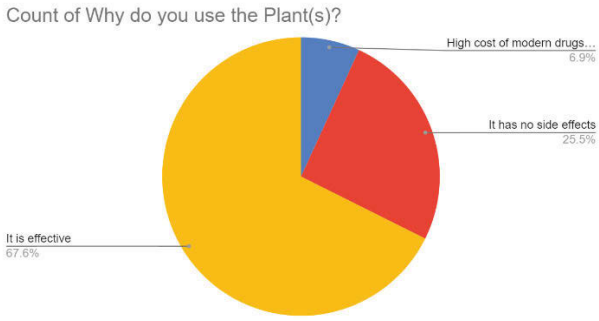

Fig. 10. Significant/Effectiveness of the plant used

Not all parts of a plant are found useful in the treatment of diseases. This is mainly due to the different distribution of phytochemicals responsible for combating diseases in plants' different parts. From the survey (Fig. 7), 55.9% of the plant part used is the bulb; this is followed by stem 19.6%. Root constitutes 16.7%, while fruits and leaves make for 6.9 % and 1.0% respectively. This result is consistent with that of Fig. 6. The use of garlic and ginger accounts for the relationship between both figures, that is, the corresponding use of bulb and stem in Fig. 7.

How these medicinal plants are prepared is captured in Fig. 8. The most popular method used is the grinding method, with a count of 61.8%. Some plants are mixed with other non-plant and plant supplements (herbal mixture); this formed 16.7%. Decoction, swallowing, slicing, and infusion formed 3.9%, 5.9%, 27.8% and 2.0% respectively.

It was discovered that the plants used for this treatment were in abundance within the study area (Fig. 9) 92.2% of the plants were in abundance, while 7.8% were not. This finding supports the basis upon which ethnomedicine stands. The vegetative abundance of the people forms their culture and influence their relationship and use of such plants as medicine [6]. In her work on the medicinal plants used in the treatment of rheumatism in Edo state Nigeria where she found out that Three plant-species: Spondias mombin L., Dysphania ambrosioides Taub, and Pterocarpus soyauxii Jacq belonging to the family Anacardiaceae, Amaranthaceae and Fabaceae respectively were the primary plants used in that region [4].

The use of these plants in RA treatment is claimed to be hinged to its effectiveness and fewer side effects. However, some claim to use it because of the high cost of orthodox drugs (Fig. 10).

The relationship between a plant used and its plant's preparation method, abundance, and effectiveness are summarized in table 1. It can be seen that the plant(s) predominately used are garlic (56), ginger (24), Onions (10),and Turmeric (8). The part of garlic (the vastly used plant with 56 respondents) used are bulb (47), fruit (5), root (2), and stem (2). 40 respondents out of the 56 respondents prepare the bulb, fruit, or fruit through grinding. Another method of preparation of garlic plant parts includes herbal mixture, swallowing, and infusion. Only the stem was reported to be prepared through herbal mixture and infusion. At the same time, 2 respondents swallow the bulb of garlic and groundnut. The majority also reported the (garlic) plant part(s) to be plenty in abundance. The majority of the respondents (38 respondents out of 56) reported using garlic because it is effective.

Ginger's plant part reported to be used by the respondents includes root (12) and stem (12). The majority of respondents that use ginger (19 respondents out of 24 respondents) use the grinding method to prepare either the root or stem. Only 3 respondents and 2 respondents use the decoction and herbal mixture method to prepare either the bulb or stem. The majority also reported the (ginger) plant part(s) to be plenty in abundance – 15 out of the 24 respondents that use ginger reported to use ginger because it is effective. In comparison, the remaining 9 respondents use ginger because it has no side effects or high cost of modern drugs and facilities.

An onions bulb is being reported to be used. 8 respondents use the slicing method, and 2 respondents reported using the grinding method of preparation. All the 10 respondents that use onions reported the plant to be present in abundance. 5 respondent each use onions because it is effective and because it has no side effects

2 respondents use turmeric root, and 6 respondents use turmeric stem. The majority of the respondents (7 respondents) use an herbal mixture of preparation, and all the 8 respondents that use turmeric reported the

Table 1

Relationship between a plant used and its plant's preparation method, abundance & effectiveness

What plant is used in treating Rheumatism?	What part of the plant is used?	What is / are the method(s) of preparation you know?	Is the plant(s) present in abundance?	Why do you use the Plant(s)?
Bitter kola	Fruit	Chewing	Yes	It is effective
Garlic	Bulb	Grinding	Yes	It is effective
		Grinding	Yes	It is effective
		Grinding	Yes	It is effective
		Grinding	Yes	It has no side effects
		Grinding	Yes	It is effective
		Grinding	Yes	It is effective
		Grinding	Yes	It is effective
		Grinding	Yes	It is effective
		Grinding	Yes	It is effective
		Grinding	No	High cost of modern drugs and facilities
		Grinding	Yes	It is effective
		Grinding	Yes	It is effective
		Grinding	Yes	It is effective
		Grinding	Yes	It has no side effects
		Grinding	Yes	It has no side effects
		Grinding	Yes	It has no side effects
		Grinding	Yes	It is effective
		Grinding	Yes	It is effective
		Grinding	Yes	It is effective
		Grinding	Yes	It is effective
		Grinding	Yes	It is effective
		Grinding	Yes	It is effective
		Grinding	Yes	It is effective
		Grinding	Yes	It is effective
		Grinding	Yes	It is effective
		Grinding	Yes	It is effective
		Grinding	Yes	It is effective
		Grinding	Yes	It has no side effects
		Grinding	No	High cost of modern drugs and facilities
		Grinding	Yes	It is effective
		Grinding	Yes	It is effective
		Grinding	Yes	It has no side effects
		Grinding	Yes	It has no side effects
		Grinding	Yes	It is effective
		Grinding	Yes	It is effective
		Grinding	No	It has no side effects
		Herbal Mixture	Yes	It is effective
		Herbal Mixture	Yes	High cost of modern drugs and facilities
		Herbal Mixture	Yes	It is effective
		Herbal Mixture	Yes	It is effective
		Infusion	Yes	It is effective
		Swallowing	Yes	It is effective
		Swallowing	Yes	It is effective
		Swallowing	Yes	It is effective
		Swallowing	Yes	It is effective
	Fruit	Grinding	Yes	High cost of modern drugs and facilities
		Grinding	Yes	It is effective
		Grinding	Yes	It has no side effects
		Herbal Mixture	No	It is effective
		Herbal Mixture	Yes	It has no side effects
	Root	Grinding	No	It has no side effects
		Herbal Mixture	No	High cost of modern drugs and facilities
	Stem	Herbal Mixture	Yes	It is effective
		Infusion	Yes	It has no side effects

What plant is used in treating Rheumatism?	What part of the plant is used?	What is / are the method(s) of preparation you know?	Is the plant(s) present in abundance?	Why do you use the Plant(s)?
Garlic and groundnut	Bulb	Swallowing	Yes	It is effective
		Swallowing	Yes	It is effective
Gayanpepper and vegetable oil	Fruit	Grinding	Yes	It is effective
Ginger	Root	Decoction	Yes	It is effective
		Grinding	No	It has no side effects
		Grinding	Yes	High cost of modern drugs and facilities
		Grinding	Yes	It has no side effects
		Grinding	Yes	It is effective
		Grinding	Yes	It is effective
		Grinding	Yes	It is effective
		Grinding	No	High cost of modern drugs and facilities
		Grinding	Yes	It has no side effects
		Grinding	Yes	It has no side effects
		Grinding	Yes	It has no side effects
		Herbal Mixture	Yes	It is effective
	Stem	Decoction	Yes	It is effective
		Decoction	Yes	It is effective
		Grinding	Yes	It is effective
		Grinding	Yes	It is effective
		Grinding	Yes	It is effective
		Grinding	Yes	It is effective
		Grinding	Yes	It is effective
		Grinding	Yes	It has no side effects
		Grinding	Yes	It has no side effects
		Grinding	Yes	It is effective
		Grinding	Yes	It is effective
		Herbal Mixture	Yes	It is effective
Jetroper	Root	Cooking with Potassium	Yes	It is effective
Lemon grass	Leave	Decoction	Yes	It is effective
Onion/Onions	Bulb	Grinding	Yes	It is effective
		Slicing	Yes	It has no side effects
		Slicing	Yes	It has no side effects
		Slicing	Yes	It has no side effects
		Slicing	Yes	It has no side effects
		Grinding	Yes	It has no side effects
		Slicing	Yes	It is effective
		Slicing	Yes	It is effective
		Slicing	Yes	It is effective
		Slicing	Yes	It is effective
Turmeric	Root	Herbal Mixture	Yes	It is effective
		Grinding	Yes	It is effective
	Stem	Herbal Mixture	Yes	It is effective
		Herbal Mixture	Yes	It is effective
		Herbal Mixture	Yes	It is effective
		Herbal Mixture	Yes	It is effective
		Herbal Mixture	Yes	It has no side effects
		Herbal Mixture	Yes	It has no side effects

plant part(s) to be present in abundance. 6 respondents reported using the plant because of its effectiveness, while 2 respondents use turmeric because it has no side effects. Other plants used are bitter kola fruit through chewing because of its effectiveness, Gayan pepper (fruit) and vegetable oil prepared through grinding and used because of its effectiveness, jatropha root cooked with potassium and used because of its effectiveness and lemon grass leave decocted and used because of its effectiveness.

Evaluation of the knowledge source, its management, and sustenance

Owing to urbanization, most cultural practices and beliefs are eroding. The survey showed that respondents with the knowledge of plants used for treatment share the information (Fig. 13). While a few (16.7%) transfer the knowledge to their friends and 2.0% transfer to family only, 82% of the respondents transfer to family and friends (Fig. 11).

The source of the knowledge of these plants was ascertained to have mainly be gotten from neighbors and friends, family, traditional healers' self-experience, and the media (Fig 12). A vast majority got the information from neighbors, followed by ancestors and traditional healers. The media is the least source where information was gotten about the treatment of RA.

The use of media in disseminating information is on the increase; it is recommended that such a platform be used for transferring this useful information to save Jos's people from the ravaging effect of this disease on both the health of individuals and the economy at large.

Relationship between respondents' age group, educational background, and knowledge transferability

The relationship between respondents' educational background and their willingness to share this information was studied (Table 2). It was observed that secondary school graduates were more into transferring the information than graduates from a higher institution. The effect of higher education on ethnomedical perception should be carefully probed into. As it is well known, westernization significantly affects local indigenous culture and approach to traditional medicine.

Table 2

Relationship between respondents' education background and their knowledge transferability

Highest Education Background	Are you transferring this knowledge?		%
BSc/BEng/BEdu	No	3	2.94
	Yes	16	15.69
HND/Post-BasicNurse	Yes	7	6.86
MSc/PhD	Yes	5	4.90
NCE/ND/BasicNurse	Yes	19	18.63
Primary Education	No	2	1.96
	Yes	7	6.86
Secondary Education	No	2	1.96
	Yes	41	40.20
Total		102	100.00

Table 3

Relationship between respondents' education background and whom they transferred knowledge to

Education background	Whom to transfer to?	Count	%
BSc/BEng/BEdu	Family Members	2	1.96
	Family Members/Friends	13	12.75
	Friends	4	3.92
HND/Post-BasicNurse	Family Members/Friends	7	6.86
MSc/PhD	Family Members/Friends	3	2.94
	Friends	2	1.96
NCE/ND/ BasicNurse	Family Members/Friends	16	15.69
	Friends	3	2.94
Primary Education	Family Members/Friends	9	8.82
Secondary Education	Family Members/Friends	36	35.29
	Friends	7	6.86
Total		102	100.00

Fig. 11. Transfer of knowledge

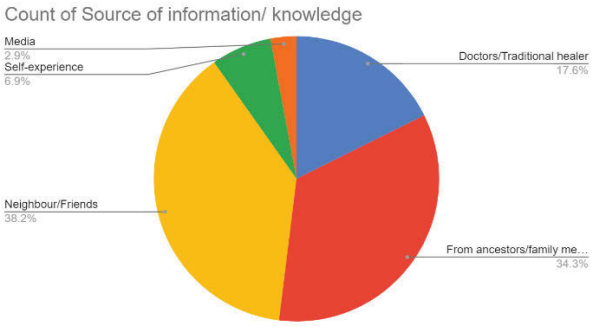

Fig. 12. Sources of the knowledge

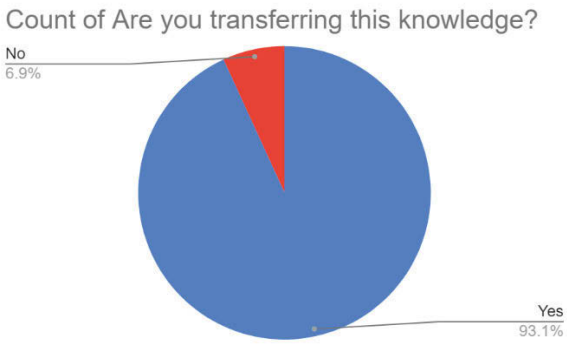

Fig. 13. Transferability of the knowledge

The respondents' age group and their willingness to share or transfer their knowledge of this traditional treatment were also examined (Fig. 13).

The transfer of this information to family and friends stand out amongst all educational background. This is a pointer to the fact that those in need of this information, regardless of family ties or not, would be given adequate knowledge.

Relationship between respondents' age group, educational background, and plant effectiveness

The respondents' testimony on this treatment's effectiveness was matched with their respective age groups in Table 4. From the table, it is observed that the respondents go for this alternative treatment because it is effective. 31.37% of those between the ages of 30 and 45 attest to it, while only 6.86%, 5.88%, claimed it has no side effects and high cost of modern drugs and facilities.

Table 4

Relationship respondent's age group with plant effectiveness

Age group	Report of plants' effectiveness	Count	%
30-45 years	The high cost of modern drugs and facilities	6	5.88
30-45 years	It has no side effects	7	6.86
30-45 years	It is effective	32	31.37
46-60 years	It has no side effects	5	4.90
46-60 years	It is effective	19	18.63
61-75 years	It is effective	7	6.86
Below 30 years	The high cost of modern drugs and facilities	1	0.98
Below 30 years	It has no side effects	14	13.73
Below 30 years	It is effective	11	10.78
Total		102	100.00

Table 5

Relationship respondents' education with plant effectiveness

Highest Education Background	Why do you use the Plant(s)?	Count	%
BSc/BEng/BEdu	High cost of modern drugs and facilities	4	3.921568627
BSc/BEng/BEdu	It has no side effects	3	2.941176471
BSc/BEng/BEdu	It is effective	12	11.76470588
HND/Post-BasicNurse	High cost of modern drugs and facilities	1	0.9803921569
HND/Post-BasicNurse	It has no side effects	2	1.960784314
HND/Post-BasicNurse	It is effective	4	3.921568627
MSc/PhD	It has no side effects	2	1.960784314
MSc/PhD	It is effective	3	2.941176471
NCE/ND/BasicNurse	High cost of modern drugs and facilities	1	0.9803921569
NCE/ND/BasicNurse	It has no side effects	6	5.882352941
NCE/ND/BasicNurse	It is effective	12	11.76470588
Primary Education	It is effective	9	8.823529412
Secondary Education	High cost of modern drugs and facilities	1	0.9803921569
Secondary Education	It has no side effects	13	12.74509804
Secondary Education	It is effective	29	28.43137255
Total		102	100

Within the age of 46-60 years, 31.37% claim it was effective, while only 4.90% claimed they took the treatment because it has no side effect.

Those between the ages of 61-75 took the treatment because they claimed it was effective. The results presented in the table pointed to the claim that this alternative form of treatment used by the people of Jos is effective and has no known side effect.

When the respondents' reason for using the plants was examined (Table 5), it was observed that graduates of higher institutions used it because it was effective, followed by the fact that it has no side effect. The high cost of modern drugs and facilities are not the major reasons for use among this category of people. The same trend is noticed among both primary and secondary graduates.

Summary of the findings

The biodata of 102 respondents revealed 67.6% of the total number of respondents to be females, while 32.4% were males (Fig. 2). The most affected population of RA was women. This reveals the reason why they may have more knowledge of the treatment of the disease than men.

Among the diverse age groups, group 30-45 years has the highest percentage, 44.1%. Fig 3. Information on respondents' educational background showed those with only secondary school background to be more knowledgeable and well informed than those with higher institution background. This could be the possible effect of urbanization (Fig.4).The survey was strictly for the inhabitants or those who have inhabited Jos before. While 5% of the total respondents are not currently within the study area, 95% of them are (Fig. 5).

The prominent plants used in the RA treatment are garlic, ginger, turmeric and onion from the survey. Garlic and onion bulbs are the parts of the plants used. The portion of ginger and turmeric used by the respondents is the stem. The high use of garlic led to the high percentage of bulbs as part of plant used in the treatment of RA (Fig. 7).

Several experimental kinds of research have been conducted on different plant part(s) of *Allium sativum* (garlic). In an ethnobotanical survey, Ogbole*et al.* reported decoction or concoction of *Allium sativum, Allium cepa, Zingiber officinale, Citrus paradise* fruits, *Citrus aurantifolia* (10 fruits), and *Alstonia boonei* bark is a recipe for rheumatoid arthritis [7]. In the same survey, a topical (cream) preparation of *Allium sativum* bulb, pure honey, and *Cassia fistula* leaves was reported to cure rheumatoid arthritis [7]. Administration of alisate

(garlic preparation of a drug) was reported to have 86.5% success rate for arthritis patients in Russia [8]. Singh *et al.* reported in a survey that local and tribal people use garlic as a natural remedy for joints and related diseases [9]. In another research, taking the juice form of garlic and salad is suggested in managing bone disease and arthritis types [10]. A review by Arreola *et al.* showed the anti-inflammatory and immunomodulatory effects of garlic [11].

The infusion of ginger (Zingiber officinale) leave was reported in a review to be used in curing rheumatoid arthritis [12].Other scientific researches have been conducted to discover the anti-inflammatory effects and pain reduction effects of active constituents of ginger [13-18]. Jackson et al. reported that curcumin strongly inhibited collagenase and stromelysin expression, suggesting its therapeutic potential for arthritis treatment [19]. In a comprehensive review by Choudhary *et al.,* it was reported that turmeric's rhizome is being traditionally used to cure arthritis [20].

Ogbole*et al.* reported the decoction of *Garcina kola* roots (bitter kola), *Combretum bracteatum* leaves, *Crateva adansonni* and *Combretum zenkeri* leaves with water to be used traditionally in treating rheumatoid arthritis [7]. Extracts of various parts of *Garcina kola* are used in traditional African medicine extensively [21]. Chemical investigations of the seeds have shown that they contain a complex mixture of phenolic compounds, including GB-type biflavonoids, xanthones, benzophenones, cycloartenol, and triterpenes [22, 23]. Kolaviron (KV) is a bioflavonoid complex isolated from the seeds of Garcinia kola and has been reported to possess neuroprotective, anti-inflammatory, antimicrobial, antioxidant, antigenotoxic and hepatoprotective activities in model systems via multiple biochemical mechanisms [24]. In another study, Kolaviron possesses anti-nociceptive and anti-inflammatory activities, both centrally and peripherally, which justifies its traditional use to relieve pain and inflammation [25, 26]. A review reveals that the root of onions (*Allium cepa*) is traditionally used to treat arthritis externally [27].

From this study, ginger, garlic, turmeric, and onions have been reported to be in abundance. The most used method of preparation of the plants is grinding. Most of the respondents use these plants because they know the plants are effective. However, these plants' safety has also been a plus as people use them because they have no side effects. From this survey, 93.1% (Fig. 11) said they transfer the knowledge of these plants. This is good and, if sustained, would lead to the preservation of this knowledge. Those who transfer the knowledge transfer to both family and friends.

CONCLUSIONS

This study has shown that knowledge about medicinal plants' use in treating rheumatoid arthritis is very much alive and relevant to Jos's people. Garlic, ginger, turmeric, and onions are the plants majorly used to treat the disease (as they have been tried), which were effective with no side effects. The transfer of this knowledge is carried and guarantees the preservation of this precious knowledge.

Gratitude. The first author acknowledges the support of the PENCIL Research Team for their contribution during the design, execution, and drafting of the report for this project.

Sources of funding. The project has no funding.

REFERENCES

1. Hajja G., Aziz B. Medicinal plants in the prevention and treatment of Rheumatoid arthritis. MOJ Bioequivalence & Bioavailability. 2018. DOI:10.15406/MOJBB.2018.05.00084
2. Liao K.P., Alfredsson L., Karlson E.W. Environmental influences on risk of rheumatoid arthritis. Curr Opin Rheumatol. 2009; 21(3):279-83. DOI: https://dx.doi.org/10.1097%2FBOR.0b013e32832a2e16
3. Emery P. Treatment of rheumatoid arthritis. BMJ. 2006 Jan 21; 332(7534):152-5. DOI: https://dx.doi.org/10.1136%2Fbmj.332.7534.152
4. Erhenhi A.H. Medicinal Plants Used for the Treatment of Rheumatism by Amador People of Edo State, Nigeria. International Journal of Plant Research. 2016; 6(1):7-12. DOI: 10.5923/j.plant.20160601.02
5. Tripathy S., Pradhan D., Anjana M. Anti-inflammatory and anti-arthritic potential of Ammania baccifera Linn. Int J. Pharm Bio Sci. 2010; 1(3):1-7. URL: https://www.researchgate.net/publication/286569799_Anti-inflammatory_and_antiarthritic_potential_of_ammania_baccifera_linn
6. Zewdie K.T. Anethnobotanical study of medicinal plants and biodiversity of trees and shrubs in Jeldu Wereda, Western Shoa Zone, Ethiopia. 2009 July. DOI: 10.13140/RG.2.2.30430.84806. URL: https://www.researchgate.net/publication/307569506_An_ethnobotanical_study_of_medicinal_plants_and_biodiversity_of_trees_and_shrubs_in_Jeldu_Wereda_Western_Shoa_Zone_Ethiopia
7. Ogbole O., Gbolade A., Ajaiyeoba E.O. Ethnobotanical survey of plants used in the treatment of inflammatory disease in the Ogun State of Nigeria. European Journal of Scientific Research. 2010; 43(2):183-91. URL: https://www.researchgate.net/publication/288417018_Ethnobotanical_survey_of_plants_used_in_treatment_of_inflammatory_diseases_in_Ogun_State_of_Nigeria
8. Denisov L.N., Andrianova I.V., Timofeeva S.S. [Garlic effectiveness in rheumatoid arthritis]. Ter Arkh. 1999; 71(8):55-8. [in Russian]. PMID: 10515039. URL: https://pubmed.ncbi.nlm.nih.gov/10515039/
9. Singh H., Krishna G., Baske P.K. Plants used in treatment of joints diseases (rheumatism, arthritis, gout and lumbago) in Mayurbhanj district of Odisha, India. Rep Opin. 2010 January; 2(9):22-6. URL: https://www.researchgate.net/publication/313001859_Plants_used_in_the_treatment_of_joint_diseases_rheumatism_

arthritis_gout_and_lumbago_in_Mayurbhanj_district_of_Odisha_India
10. Tyagi D.K., Kumar S., Joshi N. Role of different juices in the management of osteoarthritis, rheumatoid arthritis and backache - a review. J. Ayurveda integr Med Sci. 2017; 2(1):162-6. URL: https://www.jaims.in/index.php/jaims/article/view/174
11. Arreola R., Quintero-Fabián S., López-Roa R.I. Immunomodulation and anti-inflammatory effects of garlic compounds. J. Immunol Res. 2015; Article ID: 401630. DOI: https://doi.org/10.1155/2015/401630
12. Mikali P., Shayegh J., Asghari M.H. Review on the indigenous use and ethnopharmacology of hot and cold natures of phytomedicines in the Iranian traditional medicine. Asian Pac J Trop Mes. 2012; 2:s1189-93. DOI: https://doi.org/10.1016/S2221-1691%2812%2960382-7
13. Flynn D.L., Rafferty M.F., Boctor A.M. Inhibition of human neutrophil-5 lipoxygenase activity by gingerdione,shogaol, capsaicin and related pungent compounds. Prostaglandins Leukotrienes and Medicine. 1986 Oct; 24(2-3):195-8. DOI: https://doi.org/10.1016/0262-1746(86)90126-5
14. Young H.Y., Luo Y.L., Cheng H.Y., Hsieh W.C., Liao J.C., Peng W.H. Analgesic and anti-inflammatory activities of [6]-gingerol. Journal of Ethnopharmacology. 2005 Jan 4; 96(1-2):207-10. DOI: https://doi.org/10.1016/j.jep.2004.09.009
15. Sharma J.N., Srivastava K.C., Gan E.K. Suppressive effects of eugenol and ginger oil on arthritic rats. Pharmacology. 1994 Nov; 49(5):314-8. DOI: https://doi.org/10.1159/000139248
16. vanBreemen R.B., Tao Y., Li W. Cyclooxygenase-2inhibitors in ginger (Zingiberofficinale). Fitoterapia. 2011 Jan; 82(1):38-43. DOI: https://www.researchgate.net/deref/http%3A%2F%2Fdx.doi.org%2F10.1016%2Fj.fitote.2010.09.004
17. Phan P.V., Sohrabi A., Polotsky A., Hungerford D.S., Lindmark L., Frondoza C.G. Ginger extract components suppress induction of chemokine expression in human synoviocytes. Journal of Alternative and Complementary Medicine. 2005 Feb; 11(1):149-54. DOI: https://doi.org/10.1089/acm.2005.11.149
18. Haghighi M., Khalvat A., Toliat T., Jallaei S. Comparing the effects of ginger (Zingiber officinale) extract and ibuprofenon patients with osteoarthritis. Archives of Iranian Medicine. 2005 Aug; 8(4):267-71. URL: https://www.researchgate.net/publication/235007127_Comparing_the_Effects_of_ginger_Zingiber_officinale_extract_and_ibuprofen_On_patients_with_osteoarthritis
19. Jackson J.K., Higo T., Hunter W.L., Burt H.M. The antioxidants curcumin and quercetin inhibit inflammatory processes associated with arthritis. Inflam Res. 2006 Apr; 55(4):168-75. DOI: https://doi.org/10.1007/s00011-006-0067-z
20. Choudhary M., Kumar V., Malhotra H., Singh S. Medicinal plants with potential anti-arthritic activity. Journal of Intercultural Ethnopharmacology. 2015 Apr-Jun; 4(2):147-79. DOI: https://dx.doi.org/10.5455%2Fjice.20150313021918
21. Xu H.X., Mughal S., Taiwo O., Lee S.F. Isolation and characterization of an antibacterial biflavonoid from an African chewing stick Garcinia kola Heckel (Clusiaceae). J Ethnopharmacol. 2013 May 20; 147(2): 497-502. DOI: https://doi.org/10.1016/j.jep.2013.03.047
22. Antia B.S., Pansanit A., Ekpa O.D., Ekpe U.J., Mahidol C., Kittakoop P. Alpha-glucosidase inhibitory, aromatase inhibitory and antiplasmodial activities of a biflavonoid GB1 from Garcinia kola stem bark. Planta Med. 2010 Feb; 76(3):276-77. DOI: https://doi.org/10.1055/s-0029-1186081
23. Seanego C.T., Ndip R.N. Identification and antibacterial evaluation of bioactive compounds from Garcinia kola (Heckel) seeds. Molecules. 2012 May 31; 17(6):6569-84. DOI: https://doi.org/10.3390/molecules17066569
24. Adaramoye O.A., Farombi E.O., Adeyemi E.O., Emerole G.O. Inhibition of human low density lipoprotein oxidation by flavonoids of Garcinia kola seeds. Pak J Med Sci. 2005; 21(3):331-9.
25. Onasanwo S.A., Rotu R.A. Antinociceptive and anti-inflammatory potentials of kolaviron: Mechanisms of action. J. Basic Clin. Physiol. Pharmacol. 2016; 27(4):363-70. DOI: https://doi.org/10.1515/jbcpp-2015-0075
26. Ibironke G.F., Fasanmade A.A. Analgesic and central nervous system depressant activities of kolaviron. (AGarcina kola biflavonoid complex). Afr. J. Biomed. Res. 2015; 18(3):217-23. URL: https://www.ajol.info/index.php/ajbr/article/view/126140
27. Patel D., Kaur G., Sawant M.G., Deshmukh P. Herbal medicine – A natural cure to arthritis. Indian journal of natural products and resources. 2013; 4(1):27-35. URL: https://www.researchgate.net/publication/274076263_Herbal_Medicine_-_A_natural_cure_to_arthritis

Conflicts of interest: authors have no conflict of interest to declare.
Received: 04.12.2020
Revised: 16.12.2020
Accepted: 22.12.2020

ЭТНОБОТАНИЧЕСКОЕ ИССЛЕДОВАНИЕ РАСТЕНИЙ, ИСПОЛЬЗУЕМЫХ ПРИ ЛЕЧЕНИИ РЕВМАТОИДНОГО АРТРИТА: ПРИМЕР ИССЛЕДОВАНИЯ В ПРОВИНЦИИ ДЖОС (НИГЕРИЯ)

[1]Тонгшувар Г.Т., [2]Оджетунде А.О., [3]Ойегоке А.Ф., [4]Ойегоке Т.

[1] Федеральный университет, Дуцин-ма, Нигерия
[2] Технологический университет Ладоке Акинтола, Огбомошо, Нигерия
[3] Больница Салама, Зария, Нигерия
[4] Университет Ахмаду Белло, Зария, Нигерия
geoffreytimothytongshuwar@gmail.com

Актуальность. Ревматоидный артрит (РА) – аутоиммунное заболевание, приводящее к воспалению суставов. Это воспаление проявляется протрузией синовиальных сумок, сильными болями и, в дальнейшем, повреждением костей. Точная этиология этого заболевания еще не установлена. Тем не менее, существует утверждение о взаимодействии генетических факторов и факторов окружающей среды. РА – одно из заболеваний бедных людей Джоса в Нигерии из-за высокой стоимости ортодоксальной медицины.

Цель: исследование проводилось с целью сбора информации и выявления растений, используемых для лечения ревматоидного артрита в провинции Джос (Нигерия), в дополнение к доступным растениям.

Материалы и методы. Использовалась электронная анкета для получения информации от респондентов.

Результат. Установлено использование восьми видов растений. В первую очередь, использовали такие растения, как: чеснок (Allium sativum), имбирь (Zingiber officinale), куркума (Curcuma longa) и лук (Allium cepa). Использовали луковицы и стебель растений. Выявлено, что их готовили путем измельчения и приготовления травяной смеси. Употребление отваров и жевание растений было не распространено. Респонденты сообщили о своей готовности поделиться этой информацией, как с семьей, так и с друзьями.

Вывод. Это исследование показывает доступность традиционного лечения РА и сохранение вербальной формы передачи знаний.

Ключевые слова: ревматоидный артрит (РА), этномедицина, лечение, лекарственные растения, Джос.

ЕТНОБОТАНІЧНЕ ДОСЛІДЖЕННЯ РОСЛИН, ЯКІ ВИКОРИСТОВУЮТЬСЯ ПРИ ЛІКУВАННІ РЕВМАТОЇДНОГО АРТРИТУ: ПРИКЛАД ДОСЛІДЖЕННЯ В ПРОВІНЦІЇ ДЖОС (НІГЕРІЯ)

[1]Тонгшувар Г.Т., [2]Оджетунде А.О., [3]Ойєгоке А.Ф., [4]Ойєгоке Т.

[1] Федеральний університет, Дуцин-ма, Нігерія
[2] Технологічний університет Ладоке Акінтола, Огбомошо, Нігерія
[3] Лікарня Салама, Зарія, Нігерія
[4] Університет Ахмаду Белло, Зарія, Нігерія
geoffreytimothytongshuwar@gmail.com

Актуальність. Ревматоїдний артрит (РА) – аутоімунне захворювання, що приводить до запалення суглобів. Це запалення проявляється протрузією синовіальних сумок, сильними болями і в подальшому пошкодженням кісток. Точна етіологія цього захворювання ще не встановлена. Проте, існує твердження про взаємодію генетичних факторів і факторів навколишнього середовища. РА – одне із захворювань бідних людей Джос в Нігерії через високу вартість ортодоксальної медицини.

Мета: дослідження проводилося з метою збору інформації та виявлення рослин, які використовуються для лікування ревматоїдного артриту в провінції Джос (Нігерія), на додаток до наявних рослин.

Матеріали і методи. Використовувалася електронна анкета для отримання інформації від респондентів.

Результат. Встановлено використання восьми видів рослин. В першу чергу, використовували такі рослини, як: часник (Allium sativum), імбир (Zingiber officinale), куркума (Curcuma longa) і цибуля (Allium cepa). Використовували цибулини і стебло рослин. Виявлено, що їх готували шляхом подрібнення і приготування трав'яної суміші. Вживання відварів і жування рослин було не поширене. Респонденти повідомили про свою готовність поділитися цією інформацією як з родиною, так і з друзями.

Висновок. Це дослідження показує доступність традиційного лікування РА і збереження вербальної форми передачі знань.

Ключові слова: ревматоїдний артрит (РА), етномедицина, лікування, лікарські рослини, Джос.

DOI: https://doi.org/10.32345/2664-4738.4.2020.07
UDC 616-007-053.1

MODERN VIEWS REGARDING THE ETIOPATHOGENESIS, DIAGNOSTIC, TREATMENT AND PREVENTION OF APERT SYNDROME

[1]***Antsupva V.V.*** (https://orcid.org/0000-0002-7849-2602)
[2] ***Lastivka I.V.*** (https://orcid.org/0000-0002-9088-1301)
[3] ***Kolubakin D.V.*** (https://orcid.org/0000-0002-6866-9590)
[1] ***Ushko I.A.*** (https://orcid.org/0000-0003-3017-7766)
[1] ***Nahornyi O.V.*** (https://orcid.org/0000-0002-8271-5151)

[1]*Bogomolets National Medical University, Kyiv, Ukraine*
[2]*Bukovinian State Medical University, Chernivtsi, Ukraine*
[3]*Chernivtsi Regional Perinatal Center, Chernivtsi, Ukraine*

Relevance. Acrocephalosyndactyly – a group of syndromes of multiple congenital malformations (MCM), the main components of which are acrocephaly and syndactyly. The most common nosological form of this group is Apert syndrome. Given the manifestation of the syndrome at birth and severe congenital defects of the musculoskeletal system, brain, cardiovascular system and others, this disease is of practical interest to doctors of many specialties.

Objective: to generalize modern ideas about the pathogenetic mechanisms, diagnostic, treatment and prevention of Apert syndrome.

Materials and methods. Clinical case of Apert syndrome. Clinical and genealogical, biochemical, cytogenetic, instrumental methods of examination.

Results. The paper presents a clinical case of Aper syndrome in a newborn girl with multiple malformations. Modern information on pathogenetic mechanisms, diagnostic, treatment and prevention of Aper's syndrome is provided.

Conclusions. Apert syndrome belongs to a group of syndromes of multiple congenital malformations that require the attention of doctors of various specialties. The main clinical manifestations of the disease are quite specific which allows to establish the diagnosis at birth. At the core of Aper's syndrome are mutations in the FGFR2 gene. There is prenatal diagnostic of the disease. Reconstructive surgical methods of treatment have been developed. Timely comprehensive treatment and rehabilitation allow such patients to adapt to society.

Key words: acrocephalosyndactyly, Apert syndrome, FGFR2 gene mutations, syndromic craniostosis, craniofacial dysostosis.

Relevance. Acrocephalosyndactylies – a group of syndromes of multiple congenital malformations (MCM), the main components of which are acrocephaly and syndactyly. The most common nosological form of this group is Apert syndrome [1-5]. Given the manifestation of the syndrome at birth and severe congenital defects of the musculoskeletal system, brain, cardiovascular system and others, this disease is of practical interest to doctors of many specialties. Apert syndrome is inherited by autosomal dominant (AD) pattern. The frequency of Apert syndrome is 1 case per 100-200 thousand newborns. The gender ratio is 1:1. There is a link between older parents and the formation of Apert syndrome. Almost all published cases are sporadic due to the emergence of new mutations. The probability of having another baby with Apert syndrome in healthy parents was low, and the risk for children of a person with Apert syndrome is 50% [3, 4, 6]. Despite the severe external manifestations of the disease, almost half of patients have a normal level of intelligence. Early comprehensive treatment with subsequent rehabilitation allows to adapt such patients in society [7].

Objective: to generalize modern ideas about the pathogenetic mechanisms, diagnostic, treatment and prevention of Apert syndrome.

MATERIALS AND METHODS

Clinical case of Apert syndrome, used clinical and genealogical, biochemical, cytogenetic, instrumental methods of examination. Scientific publications on the definition of modern views on pathogenetic mechanisms, diagnostic, treatment and prevention of acrocephalosyndactyly have been studied.

RESULTS AND THEIR DISCUSSION

The syndrome was first described in 1894 by S. Wheaton. In 1906, the French pediatrician Eugene Apert published observations of 9 patients, and in 1920 Edwards Park and Grover Powers wrote a detailed review [3, 4]. At present, Apert syndrome is divided into 2 subtypes. Classic Apert syndrome (subtype I), which is characterized by typical for this syndrome acrocephaly and severe syndactyly, which can be compared with a «spoon» when all the fingers are fused, and a «mitten»

or «obstetrician's hand» when the thumb is free and opposite fused four fingers. Apert-Crouzon syndrome (subtype II) is an intermediate form between the classic Apert and Crouzon syndromes, i.e. in this syndrome more pronounced hypoplasia of the upper jaw. At the same time, the phenomena of syndactyly are less pronounced than in typical Apert syndrome, because both the thumbs and the little fingers are free [8].

Etiopathogenesis. Apert syndrome is based on mutations in the FGFR2 gene, which is located on the long arm of chromosome 10, locus 10q26, and encodes a type 2 fibroblast growth factor receptor. Apert syndrome is caused by one of two missence mutations in the FGFR2 gene, which involves two related amino acids: S252W and P253R, in 71% and 26% of cases, respectively. Limb deformities are more severe in patients with the P253R mutation (replacement of proline with arginine at the 253rd position of the amino acid chain). Patients with this mutation also have better results after facial and skull surgeries. The cleft palate is more characteristic of patients with the S252W mutation (replacement of serine by tryptophan at the 252nd position) [5, 7].

Mutations in this gene also cause Crouzon syndrome and Pfeiffer syndrome. Receptor defect in Apert syndrome is also the cause of congenital malformations of other structures, which involve fibroblasts (walls of large vessels, heart, facial bones, trachea) [9-13].

The missense mutation in exon 7 of the FGFR2 gene damages the protein in the linker region between the second and third immunoglobulin-like domains. The study of fibroblasts showed ectopic KGFR expression of the FGFR2 region, which was associated with limb pathology. This correlation was the first genetic evidence that abnormal KGFR expression is the cause of syndactyly in Apert syndrome [3, 4, 9].

Phenotypic manifestations. The main diagnostic signs of Apert syndrome are acrocephaly and bilateral "mitten" syndactyly of the hands and feet, which are observed in 100% of cases. Deformation of a skull represents the craniosynostosis connected with early closing of coronal and other sutures. These malformations are typical and specific for the clinical diagnosis «Apert syndrome» [1-3].

Babies' body length and weight are above the 50th percentile, but over time, growth retardation begins, especially in adolescence. In 50% of cases there is mental retardation of varying severity. In neuroimaging (neurosonography, computed tomography, magnetic resonance imaging) the most common findings are agenesis of the corpus callosum, ventriculomegaly. Brain defects such as internal hydrocephalus, aplasia or hypoplasia of the corpus callosum, aplasia or hypoplasia of the transparent membrane are observed in 60% of patients. The brain is enlarged vertically and reduced in anterior-posterior size. All children have an oblique position of cheekbones [11].

Typical facial changes include: hypertelorism, exophthalmos as a result of spheno-ethmoid-maxillary hypoplasia and flattening of the orbits, antimongoloid slanting palpebral fissures. These defects are associated with craniostenosis and deformation of the cuneiform bone with the displacement of its large wings to the front. The middle parts of the face are hypoplastic, the nose is short with a flattened back, with stenosis/atresia of the nasal choanae, possible deviation of the nasal septum. The cleft of a soft palate is registered in 30% of cases. Dental anomalies, prognathism were discribed. The ears are set low, there is the likelihood of hearing loss in the future [12].

Internal organs defects, noted in Apert syndrome, include congenital heart disease (CHD) and defects of blood vessels (pulmonary artery stenosis, dextraposition of aorta, ventricular septal defect, fibroelastosis) – 10-25%; anomalies of the genitourinary system (polycystic kidney disease, hydronephrosis) – 9.6%; defects of the gastrointestinal tract – 1.5%; respiratory system defects – 1.5%. In female patients, bicornuate uterus, vaginal atresia are also described, in male patients – cryptorchidism, diaphragmatic hernia [13].

Prenatal diagnostic is possible throughout pregnancy. The ultrasound marker is the thickening of the collar space in the first trimester. If Apert syndrome is suspected in the process of prenatal diagnostic, molecular genetic research (amniocentesis) at 16 weeks of gestation and examination of parents are recommended [10, 14, 15].

In order to verify the diagnosis of «Apert syndrome» cytogenetic study is recommended to exclude chromosomal syndromes and molecular genetic diagnostic, which is based on the search for mutations [11].

The differential diagnosis of Apert syndrome is made with other acrocephalosindactylies (type II-IV): Pfeiffer, Crouzon, Saethre-Chotzen, Muenke and Jackson-Weiss syndromes [10].

There is no specific treatment for Apert syndrome to date, but palliative and symptomatic measures can significantly alleviate the patient's condition and improve their quality of life. Reconstructive operations are performed to correct craniofacial changes. Surgical treatment is aimed at increasing the volume of the skull and correction of syndactyly. Neurosurgical treatment includes early cranioectomy of the coronal suture and fronto-orbital reposition [9].

Prevention consists in planned management of pregnancy, at the burdened family anamnesis, obligatory medical and genetic consultation, which consists in specification of the genetic diagnosis, explanation of risk of transfer of a disease to descendants, possibilities of molecular genetic research, detection of a mutation with the subsequent prenatal diagnostic. Prenatal ultrasound diagnostic of Apert syndrome is difficult due to the late formation of synostosis, which can be detected in the early third trimester of pregnancy [15].

The minimum set of observations includes regular examinations by surgeons, neurologists, ophthalmologists, pediatricians. At high intracranial

pressure immediate decompression of a skull is required. Respiratory abnormalities can lead to early death and require active treatment. Hearing can be severely reduced due to chronic otitis or abnormalities of the inner ear. Exophthalmos increases the risk of corneal ulcers. Children do not adapt well in society. Life prognosis is favorable, life expectancy up to 60 years [10, 15].

As an illustration, we present a clinical observation of Apert syndrome in a newborn girl with multiple congenital malformations. The child's parents are phenotypically healthy, the mother is 27 years old, the father is 28. The marriage is registered, not blood related. The mother of the child has a history of menstrual irregularities and operated on an ovarian cyst, taking Duphaston. During pregnancy there was edema of the lower extremities, at 37 weeks there was polyhydramnios. Heredity of both parents is burdened by oncopathology. Parental work is related to chemical and physical factors. According to the mother, the child's father drinks alcohol every week.

The child was examined by a neonatologist, geneticist and narrow specialists in the first days of life. The girl is from the first desired, unplanned pregnancy, which took place against the background of anemia, the threat of miscarriage and polyhydramnios. She was born at 38 weeks of gestation naturally. Apgar score at birth – 7/7 points. Anthropometric data at the birth of the child: body weight – 3050 g, body length – 50 cm, head circumference – 33 cm, chest circumference – 33 cm. The child's condition is serious. There are signs of craniofacial dysostosis (acrocephaly), beveled occiput, narrowing of the nasal passages, depressed nasal bridge, exophthalmos, cleft hard and soft palate, skin and bone syndactyly of both hands, skin syndactyly of the toes of both feet, moderately pronounced deformity. Neurological status: physiological reflexes of the neonatal period are suppressed, muscle tone and tissue turgor are reduced. A feed is per a feeding tube.

Due to the development of respiratory disorders (respiratory failure of the II degree) the girl was transferred to the intensive care unit. Later, the child was treated in the neonatal pathology department. General condition at admission of moderate severity due to neurological symptoms and multiple congenital malformations. The child underwent a comprehensive examination. Ultrasound scan of the heart: a patent foramen ovale up to 3.0 mm, additional chord of the left ventricle. Ultrasound scan of the abdominal cavity: no pathology detected. Neurosonography: interhemispheric gap – 2 mm, vascular plexuses are inhomogeneous; partial agenesis of the corpus callosum; moderate dilatation of the lateral ventricles. Cytogenetic study: normal female karyotype 46, XX. The parents refused the molecular genetic research.

Conclusions of specialists of narrow specialties. Pediatric neurologist: hypoxic-ischemic lesion of the CNS, acute course, CNS depression syndrome. Congenital defects of the CNS: partial agenesis of the corpus callosum, ventriculodylation of the first degree. Otolaryngologist: cleft soft and hard palate. Ophthalmologist: no pathology detected. Orthopedist: skin and bone syndactyly of both hands, skin syndactyly of the toes of both feet, moderate varus deformity of the feet. Geneticist: Apert syndrome. In order to correct craniofacial changes and defects of the hands and feet, reconstructive surgical treatment is recommended by an orthopedic surgeon and a maxillofacial surgeon. The family underwent medical and genetic counseling, planning for the next pregnancy and mandatory prenatal screening were recommended.

CONCLUSIONS

Thus, Apert syndrome belongs to a group of syndromes of multiple congenital malformations that require the attention of pediatricians, geneticists, cardiologists, neurologists, orthopedists and doctors of other specialties. The main clinical manifestations of the disease are quite specific, which allows to

establish the diagnosis at birth. Apert syndrome is based on mutations in the FGFR2 gene, which can be detected by molecular genetic research. At present, there are opportunities for prenatal diagnostic of the disease. Reconstructive surgical treatments have also been developed. Timely comprehensive treatment and rehabilitation allow such patients to adapt to society.

REFERENCES

1. Kenneth L. Jones. Hereditary syndromes according to David Smith. Atlas-reference, 2011: 498-9.
2. Hrechanina YB, Khmil OB. [Clinical case. Apert-Crouzon syndrome, associated with mitochondrial dysfunction, amino acid and lipid metabolism disorders]. Clinical genetics and perinatal diagnostics. 2018; 1(4):105-6. [in Ukrainian] URL: http://medlib.dp.gov.ua/jirbis2/images/fond_publications/Klinichna_henetyka_i_peryn_nadiahnostyka/klinichna_henetyka_i_perynatalna_diahnostyka_2018_1.pdf
3. Villarreal-Becerra E., Guerrero-Guevara R., Espías-Gómez A., Leonard R.H.Jr., Chimenos-Küstner E. General and Oral Aspects in Apert Syndrome: Report of a Case. Clinical Medical Reviews and Case Reports, 2015 Aug; 2:3. DOI: http://dx.doi.org/10.23937/2378-3656/1410050 URL: https://www.researchgate.net/deref/http%3A%2F%2Fdx.doi.org%2F10.23937%2F2378-3656%2F1410050
4. Mostafa K.G., Rasul C.H., Baruri N.N., Rahman S.M. Apert Syndrome. Bang Med J Khulna. 2012 Apr; 44(1-2): 25-7. DOI: https://doi.org/10.3329/bmjk.v44i1-2.10473. URL: https://www.researchgate.net/deref/http%3A%2F%2Fdx.doi.org%2F10.3329%2Fbmjk.v44i1-2.10473
5. Saikat Datta, Sandip Saha, Arnab Kar, Souvonik Mondal, Syamantak Basu. Apert Syndrome. Journal of the association of physicians of India. 2014 Sep; 62(9): 73-4. PMID: 26259326. URL: https://www.researchgate.net/publication/280968560_Apert_Syndrome
6. Gudipaneni Ravi Kumar, Mandapati Jyothsna, Syed Basheer Ahmed, Ketham Reddy Sree Lakshmi. Apert's Syndrome. International Journal of Clinical Pediatric Dentistry. 2014 January-April; 7(1):69-72. DOI: https://dx.doi.org/10.5005%2Fjp-journals-10005-1239
7. Reiner D., Arnaud E., Cinalli G., Sebag G., Zerah M., Marchac D. Prognosis for mental function in Apert's syndrome. J Neurosurg. 1996 Jul; 85: 66-72. DOI: https://doi.org/10.3171/jns.1996.85.1.0066
8. Khmara T. V., Shevchuk K. Z., Morarash Y. A., Ryznychuk M. O., Stelmakh G. Ya. [Ontology of the Congenital Malformation of the Pectoral Girdle Bones]. Ukrainian Journal of Medicine, Biology and Sport. 2020; 5(3): 98-106. [in Ukrainian]. DOI: https://doi.org/10.26693/jmbs05.03.098
9. Das S., Munshi A. Research advances in Apert Syndrome. Journal of Oral Biology and Craniofacial Research. 2018 Sep-Dec; 8(3):194-9. DOI: https://dx.doi.org/10.1016%2Fj.jobcr.2017.05.006
10. Hilton. C. An Exploration of the Cognitive, Physical and Psychosocial Development of Children with Apert Syndrome. International Journal of Disability, Development and Education. 2017; 64:198-210. DOI: https://doi.org/10.1080/1034912X.2016.1194379
11. Driessen C., van Veelen M.L.C., Joosten K.F.M., Versnel S.L., van Nieuwenhoven C.A., Wolvius E.B., Bredero-Boelhouwer H.H., Arnaud E., Mathijssen I.M.J. Apert Syndrome: the Paris and Rotterdam philosophy. Expert opinion on orphan drugs. 2017; 5(7): 599-605. DOI: https://doi.org/10.1080/21678707.2017.1335195
12. Koca T.T. Apert Syndrome: A case report and review of the literature. North Clin Istanb. 2016; 3(2): 135-139. DOI: https://dx.doi.org/10.14744%2Fnci.2015.30602
13. Liu Ch., Cui Y., Luan J., Zhou X., Han J. The molecular and cellular basis of Apert Syndrome. Intractable & Rare Diseases Research. 2013 Nov; 2(4):115-122. DOI: https://dx.doi.org/10.5582%2Firdr.2013.v2.4.115
14. Vieira C., Teixeira N., Cadilhe A., Reis I. Apert Syndrome: prenatal diagnosis challenge. BMJ Case Reports. 2019 Dec 9; 12(12):e231982. DOI: https://doi.org/10.1136/bcr-2019-231982
15. Lorente Molto FJ, Bonete Lluch DJ, Garrido IM. Congenital pseudarthrosis of the clavicle: a proposal for early surgical treatment. J Pediatr Orthop. 2001 Sep-Oct; 21(5): 689-93. PMID: 11521043. URL: https://pubmed.ncbi.nlm.nih.gov/11521043/

Conflicts of interest: authors have no conflict of interest to declare.
Received: 19.11.2020
Revised: 05.12.2020
Accepted: 22.12.2020

СУЧАСНІ ПОГЛЯДИ НА ЕТІОПАТОГЕНЕЗ, ДІАГНОСТИКУ, ЛІКУВАННЯ ТА ПРОФІЛАКТИКУ СИНДРОМУ АПЕРА

[1]Анцупова В.В., [2]Ластівка І.В., [3]Колубакін Д.В., [1]Ушко Я.А., [1]Нагорний О.В.

[1]Національний медичний університет імені О.О. Богомольця, Київ, Україна
[2]Буковинський державний медичний університет, Чернівці, Україна
[3]Чернівецький обласний перинатальний центр, Чернівці, Україна
antsupovavita@gmail.com

Актуальність: Акроцефалосиндактилії – група синдромів множинних уроджених вад розвитку (МУВР), основними компонентами яких є синдромальний краніостоз та синдактилія. Найбільш поширеною нозологічною формою з цієї групи є синдром Апера. Враховуючи маніфестацію синдрому вже при народженні та тяжкі вроджені вади опорно-рухового апарату,

головного мозку, серцево-судинної системи та інші, це захворювання представляє практичний інтерес для лікарів багатьох спеціальностей.

Ціль: узагальнити сучасні уявлення щодо патогенетичних механізмів, діагностики, лікування та профілактики синдрому Апера.

Матеріали та методи. Клінічний випадок синдрому Апера. Клініко-генеалогічний, біохімічний, цитогенетичний, інструментальний методи обстеження.

Результати. В роботі наведено клінічний випадок синдрому Апера у новонародженої дівчинки з вродженими множинними вадами розвитку. Надано сучасну інформацію щодо патогенетичних механізмів, діагностики, лікування та профілактики синдрому Апера.

Висновки. Синдром Апера відноситься до групи синдромів множинних уроджених вад розвитку, які потребують уваги лікарів різних спеціальностей. Основні клінічні прояви захворювання доволі специфічні, що дозволяє встановити діагноз вже при народженні. В основі синдром Апера є мутації гену FGFR2. Існує пренатальна діагностика захворювання. Розроблені реконструктивні хірургічні методи лікування. Своєчасне комплексне лікування та реабілітація таких пацієнт надають їм змогу адаптуватися у соціумі.

Ключові слова: акроцефалосиндактилія, синдром Апера, мутації гену FGFR2, синдромальний краніостоз, черепно-лицевий дизостоз.

СОВРЕМЕННЫЕ ПРЕДСТАВЛЕНИЕ ОБ ЭТИОПАТОГЕНЕЗЕ, ДИАГНОСТИКЕ, ЛЕЧЕНИИ И ПРОФИЛАКТИКЕ СИНДРОМА АПЕРА

[1]Анцупова В.В, [2]Ластивка И.В., [3]Колубакин Д.В., [1]Ушко Я.А., [1]Нагорный А.В.

[1]Национальный медицинский университет имени А.А. Богомольца, Киев, Украина
[2]Буковинский государственный медицинский университет, Черновцы, Украина
[3]Черновецкий областной перинатальный центр, Черновцы, Украина
antsupovavita@gmail.com

Актуальность. Акроцефалосиндактилии – группа синдромов множественных врожденных пороков развития (МВПР), основными компонентами которых служат синдромальный краниостоз и синдактилия. Наиболее распространенной нозологической формой из этой группы является синдром Апера. Учитывая манифестацию синдрома уже при рождении и тяжелые врожденные пороки опорно-двигательного аппарата, головного мозга, сердечно-сосудистой системы и другие, это заболевание представляет практический интерес для врачей многих специальностей.

Цель: обобщить современные представления о патогенетических механизмах, диагностике, лечении и профилактике синдрома Апера.

Материалы и методы. Клинический случай синдрома Апера. Клинико-генеалогический, биохимический, цитогенетический, инструментальный методы обследования.

Результаты. В работе приведен клинический случай синдрома Апера у новорожденной девочки с врожденными множественными пороками развития. Предоставлена современная информация о патогенетических механизмах, диагностике, лечении и профилактике синдрома Апера.

Выводы. Синдром Апера относится к группе синдромов множественных врожденных пороков развития, которые требуют внимания врачей различных специальностей. Основные клинические проявления заболевания довольно специфические, что позволяет установить диагноз уже при рождении. В основе синдрома Апера являются мутации гена FGFR2. Существует пренатальная диагностика заболевания. Разработанные реконструктивные хирургические методы лечения. Своевременное комплексное лечение и реабилитация дают возможность таким пациентам к адаптации в социуме.

Ключевые слова: акроцефалосиндактилия, синдром Апера, мутации гена FGFR2, синдромальный краниостоз, черепно-лицевой дизостоз.

DOI: https://doi.org/10.32345/2664-4738.4.2020.08
UDC 343.54-055.2(477):340.6

THE CASES OF DOMESTIC VIOLENCE IN PROTRACTED QUARANTINE CAUSED BY COVID-19

[1,2] Babkina O.P. https://orcid.org/0000-0001-8120-6526
[1] Ushko I.A. https://orcid.org/0000-0003-3017-7766
[3] Danylchenko S. https://orcid.org/0000-0001-5312-0231
[4] Tarasyuk V. https://orcid.org/0000-0002-8915-2443
[3]Vako I. https://orcid.org/0000-0002-0541-5761

[1]Bohomolets National Medical University, Kyiv, Ukraine
[2]Kyiv Clinical Bureau of Forensic Medicine, Kyiv, Ukraine
[3]Petro Mohyla Black Sea National University, Nicolaev, Ukraine
[4] Koretsky Institute of state and law, Kyiv, Ukraine
hpbsme@gmail.com

Relevance. The analysis demonstrated that legislative documents in Ukraine were developed to prevent and combat domestic violence, protect and respect human rights. The basic standards of the regulatory framework of Ukraine are consistent with the Istanbul Convention. A positive moment in the modern legislation of Ukraine is the establishment of restrictive measures for people who have committed domestic violence in the form of a ban on staying in a place of joint residence with a person who has suffered from domestic violence. Some recommendations on conducting a forensic medical examination in cases of domestic violence are proposed. Displayed aspects of an ethical approach in the «Rules for the Examination of Victims, Accused, and Other Persons» in order to reduce psychological trauma during the examination.

Objective: to analyze and summarize the legal and forensic aspects of providing legal assistance to victims of domestic violence in Ukraine and to offer recommendations for their improvement

Material and methods. The materials are data from available Internet sources within the spring of 2020; 68 appeals to forensic medical institutions. The analysis was performed using a descriptive method; fixation methods, statistical processing of the results.

Results. Ukraine is oriented towards European standards, including in the area of issues of prevention and counteraction to domestic violence and respect for human rights. Recommended using modern methods of fixation during data collection and further examination of the victim in order to be able to use the obtained data by the parties to criminal proceedings / Court.

Conclusions. The issue of prevention and counteraction to domestic violence needs special attention and further resolution due to the increase in domestic violence cases, especially during quarantine caused by COVID-19.

Keywords: domestic violence, legal assistance, forensic examination, Istanbul Convention, COVID-19.

Relevance. The problem of developing ways to prevent and combat domestic violence is one of the most pressing in all countries of the world, including Ukraine. In the wake of the COVID-19 pandemic, when most people are forced to stay at home because of commonly used quarantine measures, we can see an increase in domestic violence affecting both children, adolescents, and adults regardless of gender. It is well-known that domestic violence can be applied to both women and men, but since there is a disproportion in the world today, girls and women are overwhelmingly affected by domestic violence. It should be noted that the normative acts of Ukraine put the liability for psychological, physical and sexual violence on the family when considering facts of domestic violence, especially when investigating the family violence against people who are married (registered or civil marriage) or living in a family (children, parents, relatives). Despite the high number of law enforcement appeals, there was only administrative responsibility for violence in the family that was provided by the law in 2003 [1].

The objective of the study was to analyze and summarize the legal and forensic aspects of providing legal assistance to victims of domestic violence in Ukraine and to offer recommendations for their improvement.

MATERIALS AND METHODS

The materials are data from available Internet sources of domestic violence cases during quarantine by the COVID-19 pandemic in Ukraine within the spring of 2020; data of appeals to law enforcement agencies; 68 appeals to forensic medical institutions. The analysis was performed using a descriptive method; fixation methods (photo and video) followed by statistical processing of the results.

All the procedures and experiments of this study respect the ethical standards in the Helsinki Declaration of 1975, as revised in 2008, as well as the national law.

RESULTS AND THEIR DISCUSSION

During the research process, 28 occasions of women recourse of juridical and medical assistance in cases

of single and systematic physical and moral domestic violence by their husbands or close relatives were studied. In all cases, the women showed signs of physical violence, which manifest themselves as external injuries, namely multiple sores, bruises, abrasions, scratches, or wounds. We found that in all cases by the morphological characteristics of the injuries it was possible to determine the duration of domestic violence, its one-time or multiple events, the number of blows, the mechanism of formation, and the characteristics of receiving injuries. In two cases we want to demonstrate the features of fixing and differential diagnosis of the facts of multiple (many day-long) and one-time (day-long) domestic violence (case 1 and case 2).

Case 1. A 26-year-old woman applied for juridical and medical assistance. She was subjected to systematic physical and mental domestic violence by her husband for a year. During the last week, the husband had beat up the woman several times, had multiple punches, had kicked her, hit her in the head with household items the woman repeatedly falls, lost consciousness. Also, the husband did not allow her to leave the house. After the intervention of relatives, an ambulance was called which took the woman to the hospital for examination by a medical expert. On examination, the woman showed multiple bruises of the face, oval and rounded (in the amount of 18), with clear contours, ranging in size from 1.0 x1.0 cm to 6.0 x4.0 cm, of various colors from reddish-purple to violet-yellowish. Also in the face area, multiple abrasions of an irregular linear and arched shape (38 in number) were found, measuring from 0.8 x0.6 cm to 2.9 x1.0 cm, which is covered with two types of crusts. The red crusts located at the level of the surrounding tissues and brown, which are located above the level of surrounding tissues. After the examination, the woman was also recommended to be examined by a neuropathologist, a psychologist's consultation, as well as accommodation in a rehabilitation center. The medical experts concluded that the different colors of the bruises indicated prolonged beating for 2-6 days. The different colors of the crusts of abrasions and their level concerning the surrounding tissues indicate a prolonged beating for 1-6 days (photo 1).

Case 2. A 34-year-old woman who was subjected to domestic violence by her husband applied for juridical and medical assistance. The husband had beat up the woman several hours, had multiple punches, had kicked her, hit her a belt on the back, the woman repeatedly falls, lost consciousness. The husband did not allow her to leave the house. After the intervention of the relatives, an ambulance was called, which took the woman to the hospital and examined by a medical expert. On examination, the woman had multiple bruises of irregular oval and banded shape (22 in number) with indistinct contours, sizes from 2.0 x 1.0 cm to 26.0 x 4.0 cm, of a single reddish-violet color. After the examination the woman in the center is also recommended to be examined by a neuropathologist, a psychologist's consultation, as well as accommodation in a rehabilitation center. Medical experts give the conclusion that the nature and color of the bruisings showed that a woman had been beaten for a long time during one day (photo 2).

As a result of the European integration, Ukraine is guided by the European standards on many issues, including those in the field of prevention and counteraction to domestic violence and respect for human rights. Ukraine became the 17th State to accede to the Istanbul Convention on November 7, 2011 (although it has not yet ratified it) and supported the main objectives of the Convention, in particular, section 1: "..protecting women against all types of violence and prevention, prosecution and eradication of violence against women and domestic violence; promoting the elimination of all forms of discrimination against women, promoting equality

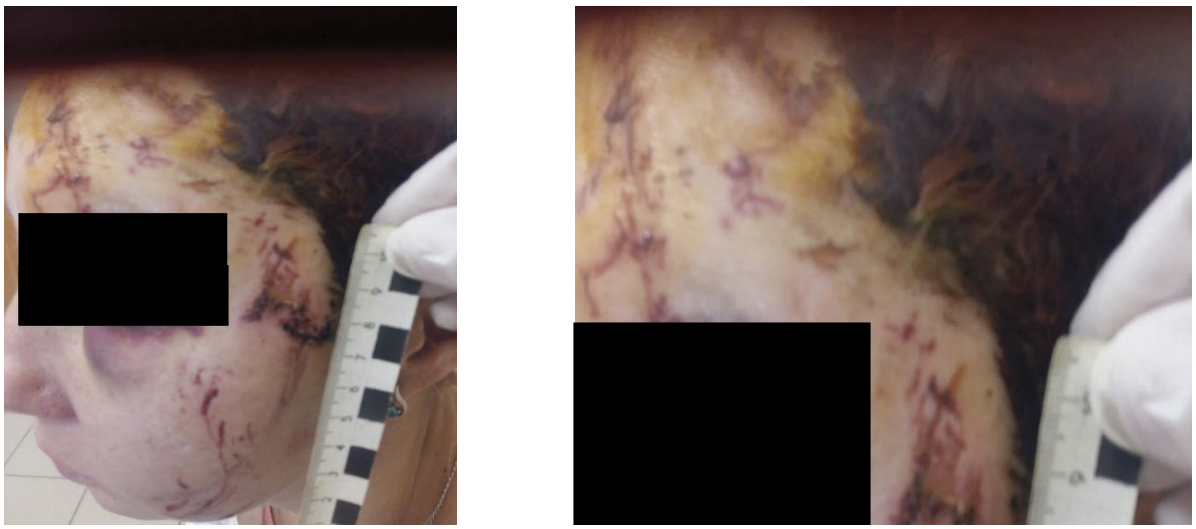

A B

Photo 1. A – The face is covered in multiple sores (general view); B – Multiple face abrasion.

A B

Photo 2. A – The back is covered in multiple sores (general view); B – The detailed view of the back soresA – The back is covered in multiple sores (general view); B – The detailed view of the back sores

between women and men and promoting women's rights; protection and assistance to all victims of violence against women and domestic violence; promoting international cooperation against these types of violence; providing support and assistance to organizations and law enforcement agencies in cooperating with one another to introduce an integrated approach to eradicating violence against women and domestic violence». However, it should be noted that despite the non-ratification of the Istanbul Convention by the Verkhovna Rada of Ukraine, the Law of Ukraine «On Amendments to the Criminal and Criminal Procedure Codes of Ukraine with a view to implementing the provisions of the Council of Europe Convention on the Prevention and Combating of Violence against Women and Domestic Violence» [2]. The adopted Law [2], as well as the Law of Ukraine «On Prevention and Countering Domestic Violence» [3], transposed the basic standards contained in the Istanbul Convention into the national law.

The Convention gives particular attention to domestic violence, especially against women, with the statement that "violence against women is defined as a violation of human rights and a form of discrimination against women and denotes all acts of gender-based violence that result or maybe physical, sexual, psychological or economic harm or suffering to women, including the threat of such acts, coercion or arbitrary deprivation of liberty, whether in the public or private life; domestic violence is one of the above types of violence, but it occurs within the family or between current or former partners, married or not, regardless of whether the offender currently lives or has lived with the victim». Thus, the Convention prohibits all forms of discrimination against women, protects their right to the life free from violence, and emphasizes the need to respect equality between women and men as one of the conditions to prevent the elimination of violence against women [4].

In addition, it should be noted that the situation regarding domestic violence combat is constantly changing in Ukraine. The situation is dramatic and causes the adoption of a number of legislative documents and amendments to existing ones. Here are some examples: the Law of Ukraine No. 2227-VIII "On Amendments to the Criminal and Criminal Procedure Codes of Ukraine with a view to implementing the provisions of the Council of Europe Convention on the Prevention of Violence against Women and Domestic Violence" (dated 06.12.2017, entered into force 11.01.2019); several amendments to the Criminal Procedure Code of Ukraine, namely the definition of domestic violence in Article 1261: «Domestic violence, that is, the intentional systematic commission of physical, psychological or economic violence against a spouse or former spouse or another person with whom the perpetrator is in (family) or close relationships, which leads to physical or psychological suffering, loss of health, loss of health, performance, emotional dependence or deterioration in the quality of life of the victim». At the same time, Article 173-2 of the Code of Administrative Offenses "Committing Domestic Violence, Gender-Based Violence, Failure to Comply with an Urgent Restraining Order, or Notifying Your Place of Stay" [5] is still working.

The Law of Ukraine No. 2229-VIII «On Prevention and Countering Domestic Violence» (adopted on 07.12.2017, entered into force on 07.01.2018) define «organizational and legal principles of prevention and counteraction to domestic violence, the main directions of implementation of the state policy in the field of prevention and counteraction domestic violence aimed at protecting the rights and interests of the victims of such violence» [3, 6].

There is also the Cabinet of Ministers of Ukraine Resolution "On Approving the Procedure for Interaction of Subjects Acting in the Field of Preventing and

Combating Domestic and Gender-Based Violence" [7] and several orders that have significantly improved the quality of legal assistance to victims of domestic violence. They are the following:

- Order of the Ministry of Internal Affairs № 654 «On Approval of the Procedure of Issuing an Urgent Injunction against the Offender by the Authorized Units of the National Police of Ukraine «, dated 01.08.2018 [8];
- Order of the Ministry of Social Policy, Ministry of Internal Affairs № 369/180 «On Approval of the Procedure for Conducting Risk Assessment of Domestic Violence» (dated 13.03.2019) [9];
- Order of the Ministry of Internal Affairs № 124 "On Approval of the Procedure for Conducting Preventive Work with an Offender by an authorized unit of the National Police of Ukraine" (dated 25.02.2019) [10].

The current legislation (Article 911 of the Criminal Procedure Code of Ukraine) provides for restrictive measures applicable to persons who have committed domestic violence:

1) "In the interests of the victim of a crime related to domestic violence, together with the punishment not related to imprisonment or release on criminal grounds or punishment provided by this Code, the court may apply to a person, the perpetrator of domestic violence, one or more restrictive measures under which the convicted person may be charged with the following duties: 1) a ban on staying in a place of cohabitation with a person affected by domestic violence; 2) restricting communication with the child if domestic violence is committed against or in the presence of the child; 3) prohibition of approaching a certain distance to a place where a person affected by domestic violence may permanently or temporarily reside, temporarily or systematically in connection with work, study, treatment or other reasons; 4) prohibition of correspondence, telephone conversations with the victim of domestic violence, other contacts through communication or electronic communications in person or through third parties; 5) referrals for the offender or probation program".

The Law clearly states that domestic violence is "the act (action or omission) of physical, sexual, psychological or economic violence perpetrated in the family or within the place of residence or between relatives, or between former or current spouses, or between other persons who co-live with one family but are not (have been) in a family relationship or are married to each other, regardless of whether the person who has committed domestic violence lives in the same place with an injured person, or not, or threatening of such acts commission»(Art. 1 Section I of the Law) [3]. There are three forms of domestic violence: psychological, physical, sexual.

Psychological abuse is "a form of domestic violence, including verbal abuse, threats, including threats against third parties, humiliation, harassment, intimidation, other acts aimed at limiting the will of a person, controlling in the reproductive sphere, if such acts or omissions caused the victim's fear for his/her own safety or the safety of a third person, have caused emotional insecurity, inability to protect themselves or have harmed the mental health of a person" (Article 14, Section I of the Law) [3].

Physical violence is "a form of domestic violence, including slaps, kicks, pushing, pinching, tapping, biting, as well as unlawful imprisonment, beating, snorting, bodily harm of varying severity, leaving in danger, not assisting a person in a life-threatening condition, causing death, committing other violent offenses" (Article 17, Section I of the Law) [3].

Sexual violence is "a form of domestic violence involving any act of a sexual nature committed against an adult without consent or against a child regardless of his or her consent, or in the presence of a child, coercion to a sexual act with a third party, and other offenses against sexual freedom or sexual integrity of a person, committed against or in the presence of a child" (Article 54, Section I of the Law) [3].

Scientists also suggested believing that the phrase «the systematic commission of physical, psychological, or economic violence» describes an act. Thus, a crime is considered to be completed if the commission of at least one of the three forms of violence (physical, psychological or economic) for the third time, resulting in at least one of the consequences listed in the Law of Ukraine "On Domestic Violence Prevention and Counteraction" [6]. It should be emphasized that the perpetrator can be brought to administrative responsibility for the first two offenses, and on the third time there is criminal liability.

In case of suspected domestic violence, law enforcement, social services, medical professionals are required to respond swiftly to an impartial investigation of impartial investigation and assistance to female and male victims of domestic violence, as well as the timely detection and fixation of psychological, physical and sexual violence.

The issue of timely appointment and expertise in cases of domestic violence arising from pre-trial investigation/ court bodies in cases of psychological, physical, and sexual abuse is quite relevant. In cases of psychological violence, the forensic psychiatric examination is foreseen, in cases of physical and sexual violence, there must be a forensic examination. Examples of physical violence are illustrated below (Photo 1 and Photo 2). In this case, it is necessary to carry out the examination of an injured woman all parts of the body and describe all available lesions (bruises, abrasions, scratches, hemorrhages, scars, etc.) in order to determine the nature of the damage, its quantity, localization, and the degree of severity of each injury.

Thus, in order to detect the existence and fixation of physical and sexual violence against victims, it is necessary to appoint and conduct a forensic medical examination in a timely manner, which is regulated by

the legal framework, namely: the Criminal Procedure Code of Ukraine, the Law of Ukraine "On Forensic Examination", and others legislative acts, international treaties and agreements on mutual legal assistance and cooperation which regulate legal relations in the field of forensic activities and normative documents, approved by orders of the Ministry of Health (Order No. 6 «On the Development and Improvement of the Forensic Medical Service of Ukraine» (dated 17.01.1995) and «The Instruction on the Forensic Examination», approved by this order, etc. [11].

Taking into account the mentioned above information about domestic violence, we recommend to follow the basic rules for conducting forensic examinations of victims, accused persons, and others and to pay attention to the following aspects:

1) to conduct interviews with the observance of moral and ethical norms, taking into account the possibility of negative situational factors that may remind the victim about the circumstances of the violence;

2) to be polite towards the victim, to formulate questions correctly, to try to create a trusting environment in order to fully describe the situation;

3) to explain clearly to the injured person that all information provided by her/ him is confidential and will not be disclosed to other persons, including the person who caused the injury;

4) it is desirable that the forensic physician be of the same sex with the victim to create comfortable situation during the survey and follow-up examination (i.e., if a female victim is affected, the forensic doctor should be female, or if the expert is a man, there must be permission from a female victim);

5) to record in full all the complaints of the victim (taking into account that sometimes the victims do not pay attention to their condition, fixing only on the psychological aspect); in cases of repeated violence, record all-time intervals, circumstances of the incident, etc .;

6) to carry out the examination of an injured woman insufficient light and at a comfortable temperature in the room, necessarily in the presence of a third person from the medical staff (nurse / medical registrar/others);

7) to inspect all parts of the body (even in cases where the victim initially refers only to blows, for example, to the area of the face or extremities); the practice shows that victims remember of their injuries in other areas after a while, sometimes after several hours or the day after the inspection;

8) to describe all available lesions (bruises, abrasions, scratches, hemorrhages, scars, etc.) according to the traditional medical scheme of description with the obligatory indication of localization, quantity and full characteristics (depending on the type of damage); if necessary to carry out research in ultraviolet rays, etc.;

9) after determining the nature of the damage, its localization, quantity, all the characteristic features, we are to establish the mechanism of damage occurrence and features of traumatic objects, the prescription of each injury, its simultaneous or different in time character of obtaining, the possibility of getting injuries in the circumstances mentioned by the victim; and the degree of severity of each injury;

10) if necessary, to send the victim to additional examinations (radiological, ultrasound, consultations of specialists such as a neurologist, cardiologist, etc.), the results of which must be taken into account in determining the severity of injuries;

11) in case of damage or other changes in the victim's clothing, to indicate this and, if necessary, recommend to law enforcement officers to order a forensic examination if this has not been done yet;

12) to carry out obligatory fixing of the damage revealed in the victim during an inspection by modern methods (photographing, etc.) additionally for the purpose of documentary confirmation;

13) to record video during data collection and further examination of the victim in order to use the obtained video data (to prevent psychological traumatization of the victim) in the course of further investigative actions, which should be reported to the party of criminal proceedings/court;

14) to remember that the competence of a forensic expert does not include the qualification of injuries such as beating, torment, and mortification. This issue is the responsibility of the pre-trial / judicial authorities.

Thus, as a result of our analysis and synthesis of legal and forensic aspects of providing legal assistance to victims of domestic violence in Ukraine, we can confidently say that Ukraine is oriented towards the European standards on many issues, including in the area of issues of prevention and counteraction to domestic violence and respect for human rights.

CONCLUSIONS

1. Ukraine together with the whole world widely uses measures to prevent and combat domestic violence and constantly develop recommendations to involve law enforcement, social services, medical institutions, public and international organizations demonstrating implementation of the European standards.
2. An effective fair investigation of domestic violence is outlined at the legislative level, including restrictive measures against domestic violence perpetrators.
3. The timely conduct of forensic examinations in order to detect the existence of injuries with the subsequent fixation of domestic violence will help the criminal/judicial side to take effective administrative, criminal, or other measures against the offender.
4. In order to prevent psychological traumatization of the injured person, it is recommended to use modern methods of fixation (photographing, video recording) during the evidence collection and further examination of

an injured person in order to be able to use the obtained data by the parties to criminal proceedings/court.

5. Due to the increasing incidence of domestic violence, especially in emergencies and lockdown situation of COVID-19, the issue of prevention and counteraction against domestic violence needs special attention and further resolution.

Acknowledgements. We thank all the members of the research team.

REFERENCES

1. Law of Ukraine 759-IV. [On Amendments to the Code of Ukraine on administrative misdemeanor installation responsibility for committing domestic violence or failure to comply with a protective order] [in Ukrainian]. URL: https://zakon.rada.gov.ua/laws/show/759-15; 2003 [accessed 15 May 2003]
2. Law of Ukraine 2227-VIII. [On Amendments to the Criminal and Criminal Procedure Codes of Ukraine with a view to implementing the provisions of the Council of Europe Convention on the Prevention and Combating of Violence against Women and Domestic Violence] [in Ukrainian]. URL: https://zakon.rada.gov.ua/laws/show/2227-19; 2017 [accessed 6 December 2017]
3. Law of Ukraine 2229-VIII. [On Prevention and Countering Domestic Violence] [in Ukrainian]. URL: https://zakon.rada.gov.ua/laws/show/2229-19. [accessed 1 January 2020]
4. [COUNCIL CONVENTION on Preventing and Combating Violence against Women and Domestic Violence (Istanbul Convention), Handbook for Members; 2013] [in Ukrainian]. URL: https://rm.coe.int/1680096e45
5. Administrative Code of Ukraine 80731-X, Article 173-2 on Administrative Offenses. [Committing Domestic Violence, Gender-Based Violence, Failure to Comply with an Urgent Restraining Order or Notification of Your Temporary Residence] [in Ukrainian]. URL: https://zakon.rada.gov.ua/laws/show/80731-10; 2020 [accessed 28 April 2020]
6. Dudorov O.O., Khavroniuk M.I. [Responsibility for Domestic and Gender-Based Violence (Scientific and Practical Commentary on the Novelties of the Criminal Code of Ukraine)]. In: Khavroniuk MI, editor. K: Waite; 2019, p. 78. [in Ukrainian]
7. CMU Resolution 658-2018-п. [On Approving the Procedure for Interaction of Subjects Performing Measures to Prevent and Combat Domestic and Gender-Based Violence] [in Ukrainian]. URL: https://zakon.rada.gov.ua/laws/show/658-2018-%D0%BF; 2018 [accessed 22 August 2018]
8. Order of the Ministry of Internal Affairs z0965-18. [On approval of the Procedure of passing by the authorized units of bodies of the National police of Ukraine the urgent restraining order against the offender] [in Ukrainian]. URL: https://zakon.rada.gov.ua/laws/show/z0965-18?lang=ru; 2018 [accessed 1 August 2018]
9. Order of the Ministry of Social Policy, Ministry of Internal Affairs z0333-19. [On approval of the Procedure for carrying out the assessment of risks of domestic violence] [in Ukrainian]. URL: https://zakon.rada.gov.ua/laws/show/z0333-19; 2019 [accessed 13 March 2019]
10. Order of the Ministry of Internal Affairs No. 124. [On approval of the Procedure for taking on preventive accounting, carrying out preventive work and removing from the preventive account of the offender by an authorized unit of the National Police of Ukraine] [in Ukrainian]. URL: https://zakon.rada.gov.ua/laws/show/z0270-19; 2019 [accessed 25 February 2019]
11. Order No. 6. [On the Development and Improvement of the Forensic Medical Service of Ukraine] [in Ukrainian]. URL: https://translate.google.com/translate?hl=ru&sl=uk&u=https://zakon.rada.gov.ua/go/z0248-95&prev=search; 1995 [accessed 17 January 1995]

Conflicts of interest: authors have no conflict of interest to declare.
Received: 10.11.2020
Revised: 29.12.2020
Accepted: 22.12.2020

ВИПАДКИ ДОМАШНЬОГО НАСИЛЬСТВА В УМОВАХ ТРИВАЛОГО КАРАНТИНУ, ВИКЛИКАНОГО COVID-19

[1,2]Бабкіна О.П., 1Ушко Я.А., [3]Данильченко С., [4]Тарасюк В., [3]Вако І.

[1]Національний медичний університет імені О.О. Богомольця, Київ, Україна
[2]Київське міське клінічне бюро судово-медичної експертизи, Київ, Україна
[3]Чорноморський національний університет імені Петра Могили, Миколаїв, Україна
[4]Інститут держави і права ім. Корецького НАН України, Київ, Україна
hpbsme@gmail.com

Актуальність. Законодавчі документи в Україні розроблені для запобігання та боротьби з домашнім насильством, для захисту і дотримання прав людини. Основні стандарти нормативно-правової бази України відповідають Стамбульській конвенції. Позитивними моментами в сучасному законодавстві України є: встановлення обмежувальних заходів для осіб, які вчинили домашнє насильство у вигляді заборони на перебування в місці спільного проживання з особою, яка постраждала від домашнього насильства; пропонуються деякі рекомендації з проведення судово-медичної експертизи; висвічуються аспекти етичного підходу в «Правилах допиту потерпілих, обвинувачених та інших осіб» з метою зменшення психологічної травми під час допиту. Але, у зв'язку зі збільшенням випадків домашнього насильства, особливо в умовах тривалого карантину, правові та судово-медичні аспекти надання правової допомоги залишаються актуальними.

Мета: проаналізувати і узагальнити правові та судово-медичні аспекти надання правової допомоги жертвам домашнього насильства в Україні та запропонувати рекомендації щодо їх поліпшення.

Матеріали та методи. Матеріалом дослідження були дані з доступних інтернет-джерел протягом весни 2020 року, аналіз 68 звернень в судово-медичні установи. Аналіз проводився описовим методом, методами фіксації, з подальшою статистичною обробкою результатів.

Результати. Показано, що Україна орієнтована на європейські стандарти, в тому числі в галузі запобігання та протидії домашньому насильству та дотримання прав людини. Впровадження сучасних методів фіксації при зборі даних і подальшому огляді потерпілого дає можливість використання отриманих даних сторонами кримінального процесу / суду.

Висновок. Питання запобігання та протидії домашньому насильству вимагає особливої уваги і подальшого вирішення у зв'язку із збільшенням випадків домашнього насильства, особливо під час карантину, викликаного COVID-19.

Ключові слова: домашнє насильство, юридична допомога, судово-медична експертиза, Стамбульська конвенція, COVID-1

СЛУЧАИ ДОМАШНЕГО НАСИЛИЯ В УСЛОВИЯХ ДЛИТЕЛЬНОГО КАРАНТИНА, ВЫЗВАННОГО COVID-19

[1,2]Бабкина Е.П., [1]Ушко Я.А., [3]Данильченко С., [4]Тарасюк В., [3]Вако И.

[1]Национальный медицинский университет имени А.А. Богомольца, Киев, Украина
[2]Киевское городское клиническое бюро судебно-медицинской экспертизы, Киев, Украина
[3]Черноморский национальный университет имени Петра Могилы, Николаев, Украина
[4]Институт государства и права им. Корецкого НАН Украины, Киев, Украина
hpbsme@gmail.com

Актуальность. Законодательные документы в Украине разработаны для предотвращения и борьбы с домашним насилием, для защиты и соблюдения прав человека. Основные стандарты нормативно-правовой базы Украины соответствуют Стамбульской конвенции. Положительными моментами в современном законодательстве Украины являются: установление ограничительных мер для лиц, совершивших домашнее насилие в виде запрета на пребывание в месте совместного проживания с лицом, пострадавшим от домашнего насилия; предлагаются некоторые рекомендации по проведению судебно-медицинской экспертизы; высвечиваются аспекты этического подхода в «Правилах допроса потерпевших, обвиняемых и других лиц» с целью уменьшения психологической травмы во время допроса. Однако, в связи с увеличением случаев домашнего насилия, особенно в условиях длительного карантина, правовые и судебно-медицинские аспекты оказания правовой помощи остаются актуальными.

Цель: проанализировать и обобщить правовые и судебно-медицинские аспекты оказания правовой помощи жертвам домашнего насилия в Украине и предложить рекомендации по их улучшению.

Материалы и методы. Материалом исследования были данные из доступных интернет-источников в течение весны 2020 года, анализ 68 обращений в судебно-медицинские учреждения. Анализ проводился описательным методом, методами фиксации, с последующей статистическая обработкой результатов.

Результаты. Показано, что Украина ориентирована на европейские стандарты, в том числе в области предотвращения и противодействия домашнему насилию и соблюдения прав человека. Внедрение современных методов фиксации при сборе данных и последующем осмотре потерпевшего дает возможность использования полученных данных сторонами уголовного процесса /суда.

Вывод. Вопрос предотвращения и противодействия домашнему насилию требует особого внимания и дальнейшего решения в связи с увеличением случаев домашнего насилия, особенно во время карантина, вызванного COVID-19.

Ключевые слова: домашнее насилие, юридическая помощь, судебно-медицинская экспертиза, Стамбульская конвенция, COVID-19.

DOI: https://doi.org/10.32345/2664-4738.4.2020.09
UDC 616.36-008.6-056.7:616.152:547.937:615:575.1

JILBER'S SYNDROME: CLINICAL AND PHARMACOLOGICAL ASPECTS. Review

Khaitovych M.V. (https://orcid.org/0000-0001-6412-3243)
Turchak D.V. (https://orcid.org/0000-0001-8799-0817)
Bogomolets National Medical University, Kyiv, Ukraine
nik3061@gmail.com

Relevance. At present, the metabolism of drugs in patients with Gilbert's syndrome will be actively studied, as it may be associated with both the risk of dose-dependent adverse reactions and treatment ineffectiveness.

Objective: to summarize the information of various authors on the peculiarities of the use of drugs in patients with Gilbert's syndrome.

Methods. Analysis of scientific publications in the international electronic scientometric database PubMed by keywords. Search depth – 10 years (2010-2019).

Results. Gilbert's syndrome is observed in 3-10% of the population and is characterized by an isolated increase of bilirubin in the blood to moderate values without changes in other biochemical parameters of liver function and without damage to its structure. Gilbert's syndrome is inherited autosomal recessively and is mainly due to the presence of an additional dinucleotide thymine-adenine (TA) in the promoter region A(TA)6TAA gene encoding the enzyme UGT1A1. Elongation of the promoter sequence reduces the formation of UGT1A1. In variant A(TA)7TAA, the level of enzyme production can be reduced to 80% of the norm in hetero- and up to 20% in homozygotes, respectively. Gilbert's syndrome is manifested by increased levels of indirect bilirubin in the blood, jaundice of the skin and mucous, abdominal pain, as well as dyspepsia and asthenovegetative syndrome. Intermittent icteric sclera and skin occur against the background of exogenous and endogenous factors such as starvation, dehydration, infectious diseases, emotional and physical stress, hemolysis, menstruation, alcohol consumption, hormonal contraception, etc., usually at a bilirubin concentration exceeding 40-45 μmol/l. Complications of hyperbilirubinemia with Gilbert's syndrome include the development of gallstone disease, including in children and adolescents. Gilbert's syndrome is associated with impaired metabolism of some drugs – aglucones. These include anabolic steroids, glucocorticoids, androgens, rifampicin, cimetidine, chloramphenicol, streptomycin, sodium salicylate, ampicillin, caffeine, ethinyl estradiol, paracetamol, ibuprofen, The clinical feature of Gilbert's syndrome is the appearance or aggravation of jaundice associated with the use of such drugs. In conditions of UGT1 deficiency, drugs compete with bilirubin for the enzyme, which leads to an increase of indirect bilirubin in the serum. Therefore, to prevent liver damage, it is necessary to assess the risk and benefit of drug treatment of patients with Gilbert's syndrome in each case.

Conclusions. Gilbert's syndrome is a common pathological condition and therefore it is important to diagnose it as early as possible. Given that the use of aglucones in patients with Gilbert's syndrome may cause the development of drug-induced liver damage, it is necessary to assess the risk and benefit of drug treatment of patients with Gilbert's syndrome in each case.

Key words: Gilbert's syndrome, drugs, metabolism, pharmacogenetics

Relevance. Gilbert's syndrome (GS) was first described in 1901 by the French gastroenterologist Augustin Nicolas Gilbert and is the most common form of hereditary pigmented hepatosis.Gilbert's syndrome is characterized by an isolated increase in the level of bilirubin in the blood to moderate values (in the range of 21-85 μmol/l) without changes in other biochemical parameters of liver function and without damage to its structure [30]. Gilbert's syndrome is observed in 3-10% of the population [18]. The prevalence of Gilbert's syndrome varies significantly in different countries, which is to some extent due to differences in diagnostic criteria.Gilbert's syndrome is more often diagnosed in boys during puberty than in girls.For men and women, the ratio of Gilbert's syndrome is 2:1 – 7:1. Pubertal age of onset of the disease is attributed of Inhibition of bilirubin glucuroning by endogenous steroid hormones.It is believed that bilirubin production is higher in men than in women [28].

Currently, in the patients with Gilbert's syndrome continue to actively study the characteristics of drug metabolism, since this may be associated with both the risk of dose-dependent adverse reactions and the ineffectiveness of treatment.

Objective: to summarize the information of various authors on the peculiarities of the use of drugs in patients with Gilbert's syndrome.

METHODS

Analysis of scientific publications in the international electronic scientometric database PubMed by keywords. Search depth – 10 years (2010-2019).

RESULTS

Etiology and pathogenesis. Hepatic bilirubin metabolism is the most important factor in determining the concentration of bilirubin in the blood of healthy peopleThe disease is based on a violation of bilirubin

conjugation due to insufficiency (≤ 40% of normal activity) of the enzyme uridine-5-diphosphate glucuronosyltransferase (UGT) 1A1 in the liver [15]. This metabolic disorder is caused by a genetic defect in the enzyme UGT1A1 [20].

Leukocytes, including macrophages, are known to remove potentially harmful heme from the extracellular space and to produce heme catabolites, including iron, carbon monoxide, and biliverdin/bilirubin. Approximately 25% of heme is derived from inefficient erythropoiesis and heme-containing enzymes, and the remaining 75% from obsolete erythrocytes that are processed in the reticuloendothelial system [34]. In macrophages, heme catabolism is first carried out by hemoxygenase (Fig. 1), with biliverdin being formed, which is then converted to bilirubin (unbound or indirect bilirubin) by biliverdin reductase.Indirect bilirubin is a lipophilic molecule and circulates in the blood plasma mainly in the albumin-bound state [34]. Albumin transports indirect bilirubin to the liver, where it, bound by ligands, diffuses into the cytosol by OATP transporter proteins [1]. In the endoplasmic reticulum, bilirubin is conjugated to mono- and diglucuronide using the UGT-1 enzyme. UGT1A1 conjugates glucuronic acid with bilirubin and converts it to water-soluble substances that can be excreted in bile.Bound bilirubin (direct bilirubin) is exported to the bile duct by transporters of the MRP2 family (multiple drug resistance protein-2), and a small amount – by transporters of MRP3 can be excreted through the sinusoidal membrane into the blood [1]. If under physiological conditions MRP expression is at a very low level, then in cholestasis, these transporters begin to be actively expressed [13].

Once in the bile, bilirubin glucuronides are first stored in the gallbladder and then sent to the intestine with other bile components that facilitate the absorption of fats and other fat-soluble compounds.Bilirubin glucuronides are then deconjugated by bacterial β-glucuronidases, with the unconjugated pigment being reduced and oxidized. Some of these products may be reabsorbed and promote the circulation of the bilirubin pool; others are excreted through the kidneys and intestines and contribute to the color of urine and feces, respectively [1].

Physiological inhibitors of UGT1A1 are the steroid hormones estrogen and testosterone, so they significantly affect the concentration of bilirubin in the blood.

Genetics. Gilbert's syndrome is inherited autosomal recessively. A genetic defect mapped to chromosome 2 at the q37 locus and due to the presence of an additional thymine-adenine (TA) dinucleotide in the promoter region A(TA) of the 6TAA gene encoding the UGT1A1 enzyme leads to the formation of region A(TA)7TAA [10]. Elongation of the promoter sequence leads to a decrease in the formation of UGT1A1. This mutation is designated UGT1A1*28 and is the most common and studied.In variant A(TA)7TAA, the level of enzyme production can be reduced to 80% of the norm in hetero- and up to 20% in homozygotes, respectively. Clinically, the syndrome is found

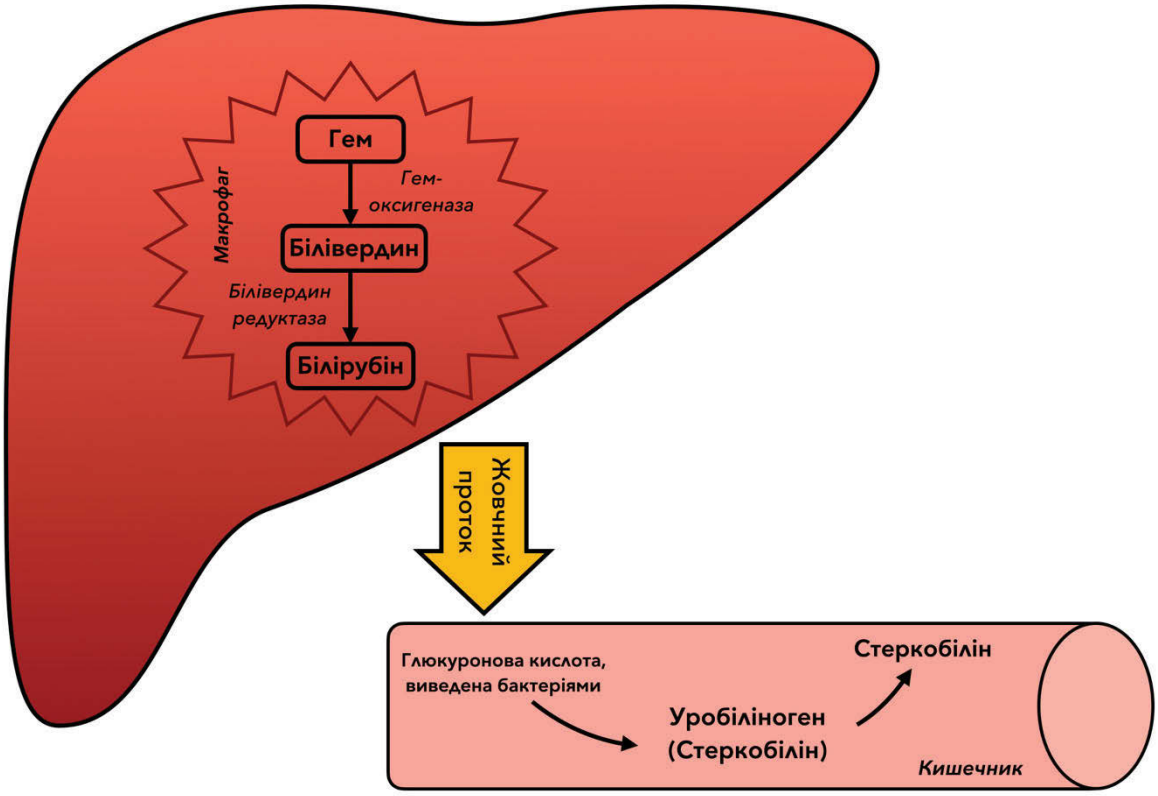

Fig. 1. Heme metabolism

in carriers of the homozygous state of this mutation, which is found in 11-16% of the population [17], while in 42% of the population the condition is heterozygous [16, 23]. In a study in Romania, 292 patients and 605 healthy people, 62% of patients showed polymorphism UGT1A1*28 (7TA), about 37% – UGT1A1*1 (6TA), the remaining 0.61% and 0.72%, respectively, options 5TA and 8TA [24]. About 58% of the experimental group had a heterozygous genotype (TA)6/7, 32% – homozygous (TA)7/7 genotype. As a rule, in heterozygous carriers, Gilbert's syndrome does not manifest clinically, however, indirect bilirubin is at the upper limit of the norm or may be slightly elevated.

There are data on the presence of up to 113 variants of mutations of this gene (UGT1A1*1–*113), including 5 exons and introns of the UGT1A1 gene, often in combination with genetic polymorphisms of other UGT1A genes,which are associated with either mild hyperbilirubinemia or life-threatening jaundice [31]. Recent genetic results indicate a dual genetic polymorphism of UGT 1A6 and 1A1 in patients with Gilbert's syndrome, leading to a defect in bilirubin glucuronidation, as well as other endogenous and exogenous substrates such as serotonin [20].

Clinical manifestations. Gilbert's syndrome is manifested by increased levels of indirect bilirubin in the blood, jaundice of the skin and mucous membranes,abdominal pain, as well as dyspepsia and asthenovegetative syndrome. Intermittent icteric sclera and skin occur against the background of exogenous and endogenous factors,such as starvation, dehydration, infectious diseases (including asymptomatic Epstein-Barr infection), emotional and physical stress,hemolysis or menstruation,alcohol consumption, hormonal contraception, etc. [17,34] usually at a bilirubin concentration exceeding 40-45 μmol/l [34].

There is evidence of delayed gastric emptying in Gilbert's syndrome, and this is explained, on the one hand, by the fact that gastrointestinal motility may affect the concentration of bilirubin, or by the fact that bilirubin may affect the motility of the gastrointestinal tract. The transit time in the gastrointestinal tract affects the concentration of bilirubin in the blood, prolonging the transit time due to decreased gastric motility during fasting, allows to absorb deconjugated glucuronides of bilirubin by passive diffusion, accompanied by an increase in circulating bilirubin 1.5-2 times [34].

Hyperserotoninemia in Gilbert's syndrome may contribute to nonspecific symptoms [20].

Complications of hyperbilirubinemia with Gilbert's syndrome include the development of gallstone disease. This was confirmed by a meta-analysis that included 2,816 patients with gallstone disease and 1,617 patients without gallstone disease. The study found that the risk of developing gallstones in Gilbert's syndrome increased by 21.2%, more often among men [5]. It should be noted that with Gilbert's syndrome, the development of gallstones can form in childhood. It was found that 76.5% of children with Gilbert's syndrome had biliary tract dysfunction; almost half of them had sludge syndrome. Gallstone disease was diagnosed in 11.8% of children [2].

The protective effect of hyperbilirubinemia is described, in particular it is manifested in a reduction in twice the mortality than in the general population [14], due to a reduced risk of diseases associated with oxidative stress [33], in particular cardiovascular diseases and metabolic syndrome [8]. According to the results of a double-blind placebo-controlled study,in which with the help of atazanavir in 16 patients with type 2 diabetes caused moderate hyperbilirubinemia for 3 days (the level of bilirubin increased on average from 7 mmol/l to 64 mmol/l), found a significant improvement in the antioxidant properties of plasma and endothelium-dependent vasodilation, a decrease in blood levels of factor Willebrand [7] with moderate hyperbilirubinemia.

For diagnostic purposes, now patients are determined by the number of TA repeats in the promoter region of the UGT1A1 gene, normally they are 6. An increase in the number of repetitions in this area indicates a decrease in the functional activity of UGT1A1. A test with a low-calorie diet is also performed for diagnostic purposes (400 kcal/day for 3 days) with the subsequent appointment of phenobarbital (0.1 g/day at night for a week). The test with a low-calorie diet is evaluated by the percentage of patients, who responded by increasing the concentration of bilirubin by 21.4 μmol/l, the test with phenobarbital is considered positive, if the level of bilirubin decreases more than 3 times from its values after a test with a low-calorie diet.

Clinical and pharmacological aspects of Gilbert's syndrome. It is known that metabolism (biotransformation) is a change in the chemical structure of medicinal preparation and their physicochemical properties under the action of enzymes in the body. The metabolism of medicinal preparation includes 2 phases: phase I or chemical modification involving mainly cytochrome P450 isoenzymes, phase II or conjugation reactions with glucuronic, sulfuric, acetic acid or amino acids.

Gilbert's syndrome has been shown to be associated with impaired metabolism of some medicinal preparation (Table.1) [25]. The clinical feature of Gilbert's syndrome is the appearance or worsening of jaundice associated with medication. In conditions of UGT1 deficiency, drugs compete with bilirubin for the enzyme,leading to an increase in indirect serum bilirubin.Such drugs are called aglucones. These include anabolic steroids, glucocorticoids, androgens, rifampicin, cimetidine, chloramphenicol, streptomycin, sodium salicylate, ampicillin, caffeine, ethinyl estradiol, paracetamol, ibuprofen,ketoprofen, sulfonamides, diacarb, menthol, statins, etc. [30]. Thus, the use of paracetamol, irinotecan, atazanavir or elvitegravir in patients with Gilbert's syndrome may be associated with frequent adverse side effects of pharmacotherapy [31].

Table 1

Medicines that are metabolized by glucuronidation

Medicines	Clinical application
Tolbutamide	Type 2 diabetes
Amidopyrine	Inflammation, fever, pain
Menthol	Pain as a decongestant
Estradiol	Menopause, prostate cancer
Lamotrigine	Epilepsy, bipolar disorder
Tricyclic antidepressants	Depression, neuropathic pain
Irinotecan	Colorectal cancer
Nonsteroidal anti-inflammatory drugs	Inflammation, fever, pain
Paracetamol	Fever, pain
HIV protease inhibitors	HIV

Back in 1999, 2 heterogeneous groups of patients with Gilbert's syndrome were described, depending on the metabolism of paracetamol. In one group he was normal,whereas in the other glucuronidation was less than 50%. Decreased glucuronidation was combined with increased oxidation,which contributed to the formation of the toxic metabolite paracetamol [9]. Subsequently, the results of a number of studies did not reveal features of paracetamol metabolism in patients with Gilbert's syndrome,which led the authors to believe that paracetamol is a substrate of another isoform of UGT [26]. It is now known that paracetamol is metabolized by isoenzymes UGT1A1, UGT1A6 and UGT1A9, therefore, the results of modern studies indicate that paracetamol is safe for patients with the Gilbert's syndrome in normal doses [22].

It should be noted that toxic metabolites of some drugs can cause the development of hyperbilirubinemia with intrahepatic cholestasis due to damage to carrier proteins of the BSEP (bilesaltexportpump) family, exporting bile acids, or transporter proteins of the MRP2 family, involved in the export of bilirubin and other molecules from the hepatocyte to the bile duct (Fig. 2). Such drugs include androgens (methyltestosterone, retabolil, nerobol) and estrogens (regividon, tricvilar, nonovlon), cytostatics (cyclosporine A), chlorpromazine, sulfonamides, semisynthetic and synthetic penicillins (oxacillin, ampicillin, amoxicillin, carbenicillin, methicillin), macrolides (erythromycin, oleandomycin), cephalosporins (ceftriaxone and ceftazidime), H2-histamine receptor blockers (cimetidine, ranitidine), oral hypoglycemic drugs - sulfonylureas (glyburide, gliclazide, glibenclamide) etc.

Side effects of antitumor drugs in patients with Gilbert's syndrome have been described [6]. In patients with Gilbert's syndrome,who received busulfan mode in hematopoietic stem cell transplantation, higher overall mortality and mortality by 200 days after transplantation [21].

Hyperbilirubinemia may often occur with chemotherapy for acute lymphoblastic leukemia. A retrospective analysis showed that 23 out of 159 patients with acute lymphoblastic leukemia had Gilbert's syndrome, these children had higher levels of hyperbilirubinemia with treatment and lower clearance of methotrexate, however, only 5 patients required changes in the treatment regimen as a result. Therefore, the authors do not consider it appropriate to screen for Gilbert's disease in all patients, but if hyperbilirubinemia is detected, appropriate diagnostic tests and changes to the treatment regimen should be performed [3].

It was found that the immunomodulator lenalidomide caused hyperbilirubinemia without activation of alkaline phosphatase, alanine aminotransferase (ALT) and aspartate aminotransferase (AST) in a 55-year-old patient with heterozygous TA7 UGT1A1, the author concluded that the unmasking of Gilbert's syndrome on the background of the use of lenalidomide [27].

It is proposed to apply Hay's law when prescribing lapatinib in patients with Gilbert's syndrome [29]. This law is an empirical rule in case the patient has a high risk of lethal drug-induced liver damage, if the drug causes hepatocellular rather than cholestatic jaundice. The drug causes two to three times the upper limit of ALT or AST,

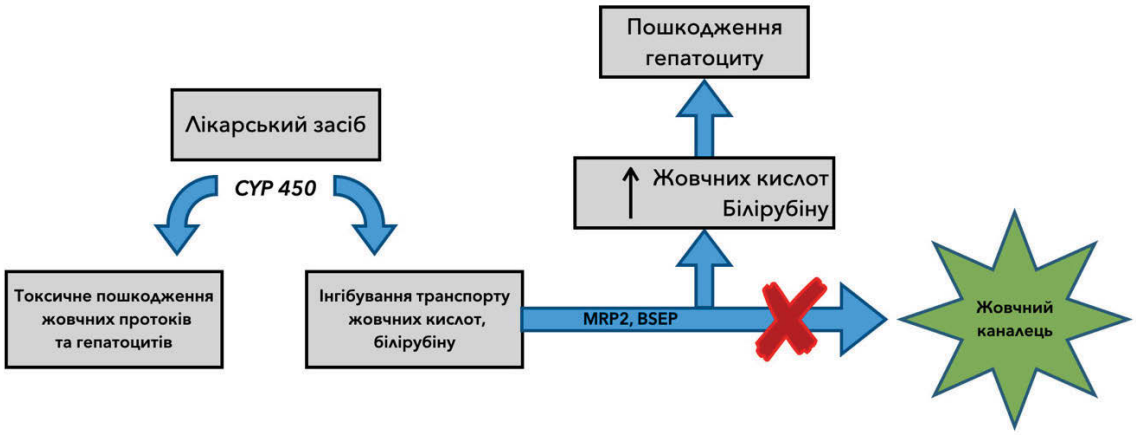

Fig. 2. The scheme of development of cholestasis as a result of the action of medicines

as well as more than 2 times the upper limit of normal serum bilirubin, without bile stagnation, there are no other reasons for this effect.

It was found that mebendazole – a broad-spectrum antiprotozoal agent, due to impaired glucuronidation caused hepatitis in patients with Gilbert's syndrome [32].

An increase in hepatic transaminases has been reported in a patient with Gilbert's syndrome with depression when taking duloxetine and venlafaxine.Desvenlafaxine did not require participation in the metabolism of the cytochrome P450 isoenzyme 2D6 and did not cause side effects [11].

Antihelicobacter therapy had a negative effect on the glucuronyltransferase system, which led to a violation of the condition in patients with genetic Gilbert's syndrome [4].

No special treatment has been proposed for patients with Gilbert's syndrome. It is proved that isotretinoin (stereoisomer of trans-retinoic acid (tretinoin), which is used to treat acne, significantly reduces blood bilirubin in patients with Gilbert's syndrome in the first 10 weeks of treatment [12, 19].

Phenobarbital and other inducers of bilirubin-UGT1 enzymes normalize plasma bilirubin levels in patients with Gilbert's syndrome. This is mainly due to the accelerated clearance of bilirubin due to the induction of enzymes, but also due to a decrease in bilirubin turnover. Steroids may also reduce plasma bilirubin in Gilbert's syndrome by increasing hepatic uptake and storage of bilirubin.

CONCLUSIONS

Thus, Gilbert's syndrome belongs to common pathological conditions and therefore it is important to diagnose it as early as possible. Considering that the use of aglucones preparations in patients with Gilbert's syndrome can be the cause of the development of medicine-induced liver damage, it is necessary in each case to assess the risk and benefit of medicine treatment for patients with Gilbert's syndrome.

REFERENCES

1. Ipatova M.G., Shumilov P.V., Shagalova D.L., Nesterova T.A., Ivanova A.S. [Features of pharmacotherapy in patients with Gilbert's syndrome]. Pediatrics. 2015; 94(6): 92-6. [in Russian] URL: https://pediatriajournal.ru/files/upload/mags/349/2015_6_4484.pdf
2. Rejzis, A.R., Hohlova, O.N., Nikitina, T.S. [Gilbert's syndrome. Contemporary views, outcomes and therapy]. Internet Doktor.ru. 2012; 3 (71): 42-5. URL: https://internist.ru/publications/detail/sindrom-zhilbera.-sovremennye-vozzreniya,-ishody-i-terapiya/
3. Berrueco R., Alonso-Saladrigues A., Martorell-Sampol L., Català-Temprano A., Ruiz-Llobet A., Toll T., Torrebadell M., Naudó M., Camós M., Rives S. Outcome and toxicities associated to chemotherapy in children with acute lymphoblastic leukemia and Gilbert syndrome. Usefulness of UGT1A1 mutational screening. Pediatr Blood Cancer. 2015 Apr; 62(7): 1195-201. DOI: https://doi.org/10.1002/pbc.25457
4. Botvin'ev K., Kolotilina A.I., Turina, I.E., Dubrovina G.M. [Effect of anti-helicobacter therapy on the hepatic glucuronyl transferase system of adolescents with Gilbert's syndrome]. Klin Med (Mosk). 2014; 92(12), 55-8. [in Russian] https://pubmed.ncbi.nlm.nih.gov/25980300/
5. Buch S., Schafmayer C., Volzke H. et al. Loci from a genome-wide analyses of bilirubin levels are associated with gallstone risk and composition. Gastroenterology. 2010; 139(6): 1942-51. DOI: https://doi.org/10.1053/j.gastro.2010.09.003.
6. Burchell B., Soars M., Monaghan G., Cassidy A., Smith D., Ethell B. Drug-mediated toxicity caused by genetic deficiency of UDP-glucuronosyltransferases. Toxicol Lett. 2000; 112-113: 333-340. DOI: https://doi.org/10.1016/S0378-4274(99)00209-X
7. Dekker D., Dorresteijn M.J., Pijnenburg M., Heemskerk S., Rasing-Hoogveld A., Burger D.M., Wagener F., Smits P. The bilirubin-increasing drug atazanavir improves endothelial function in patients with type 2 diabetes mellitus. Arterioscler Thromb Vasc Biol. 2011 Feb; 31(2): 458-63. DOI: https://doi.org/10.1161/atvbaha.110.211789
8. Erlinger S., Ariasm I.M., Dhumeaux D. Inherited disorders of bilirubin transport and conjugation: new insights into molecular mechanisms and consequences. Gastroenterology. 2014 Jun; 146(7): 1625-38. DOI: https://doi.org/10.1053/j.gastro.2014.03.047
9. Esteban A., Pérez-Mateo M. Heterogeneity of paracetamol metabolism in Gilbert's syndrome. Eur J Drug Metab Pharmacokinet. 1999; 24(1): 9-13. DOI: 10.1007/BF03190005
10. Farrar J.S., Palais R.A., Wittwer C.T. Snapback primer genotyping of the Gilbert syndrome UGT1A1 (TA)(n) promoter polymorphism by high-resolution melting. Clin Chem. 2011; 57(9): 1303-10. DOI: https://doi.org/10.1373/clinchem.2011.166306
11. Feinberg S. Correction of venlafaxine- and duloxetine-induced transaminase elevations with desvenlafaxine in a patient with Gilbert's syndrome. CNS Spectr. 2010; 15(1): 53-5. DOI: https://doi.org/10.1017/s1092852900000304
12. Fernández-Crehuet P., Fernández-Crehuet J.F., Allam M.F., Navajas R.F-C. Hepatotoxicity of isotretinoin in patients with acne and Gilbert's syndrome: a comparative study. BMJ Open. 2014; 4(3): e004441. DOI: http://dx.doi.org/10.1136/bmjopen-2013-004441
13. Fretzayas A., Moustaki M., Liapi O., Karpathios T. Gilbert syndrome. Eur J Pediatr. 2012 Jan; 171(1): 11-5. DOI: https://doi.org/10.1007/s00431-011-1641-0
14. Horsfall L.J., Nazareth I., Pereira S.P., Petersen I. Gilbert's syndrome and the risk of death: a population-based cohort study. J Gastroenterol Hepatol. 2013; 28(10): 1643-7. DOI: https://doi.org/10.1111/jgh.12279
15. Huang M-J., Chen Y-C., Huang Y-Y., Yang S-S., Chen P-L., Huang C-S. Effect of UDP-glucuronosyltransferase 1A1 activity on risk for developing Gilbert's syndrome.

Kaohsiung J Med Sci. 2019; 35(7): 432-9. DOI: https://doi.org/10.1002/kjm2.12077
16. Jiang J., Wang H.G., Wu W.L., Peng X.X. Mixed Dubin-Gilbert Syndrome: A Compound Heterozygous Phenotype of Two Novel Variants in ABCC2 Gene. Chin Med J (Engl). 2017 Apr; 130(8): 1003-5. DOI: https://doi.org/10.4103/0366-6999.204108
17. Kabícek P., Barnincová L. Juvenile hyperbilirubinaemia and its early manifestation in adolescence. Cas Lek Cesk. 2007; 146(6): 528-32. PMID: 17650591. URL: https://pubmed.ncbi.nlm.nih.gov/17650591/
18. Kamal S., Abdelhakam S., Ghoraba D., Massoud Y., Aziz K.A., Hassan H., Hafez T., Sallam A.A. The frequency, clinical course, and health related quality of life in adults with Gilbert's syndrome: a longitudinal study. BMC Gastroenterology. 2019; 19. URL: https://bmcgastroenterol.biomedcentral.com/articles/10.1186/s12876-019-0931-2
19. Kurtipek G.S., Sarı N., Akyurek F.T. Significant reduction in bilirubin levels in a patient with Gilbert's Syndrome under isotretinoin treatment for acne vulgaris: A new area of use for isotretinoin? Dermatol Ther. 2019 Mar; 32(3): e12884. DOI: https://doi.org/10.1111/dth.12884
20. Maladaki A., Yavropoulou M.P., Kotsa K., Tranga T., Ventis S., Yovos J.G. Non tumoral hyperserotoninaemia responsive to octreotide due to dual polymorphism in UGT1A1 and UGT1A6. Hormones (Athens). 2012; 11(1): 104-8. doi: 10.1007/BF03401544
21. McDonald G.B., Evans A.T., McCune J.S., Schoch G., Ostrow J.D., Gooley T.A. Mortality outcomes after busulfan-containing conditioning treatment and haemopoietic cell transplantation in patients with Gilbert's syndrome: a retrospective cohort study. Lancet Haematol. 2016; 3(11): e516-e525. DOI: https://doi.org/10.1016/S2352-3026(16)30149-1
22. Nakagawa T., Mure T., Yusoff S., Ono E., Harahap I.S.K., Morikawa S. et al. Acetaminophen administration in a patient with Gilbert's syndrome. Pediatr Int. 2012; 54(6): 934-6. DOI: https://doi.org/10.1111/j.1442-200X.2012.03602.x
23. Pasha Y.Z., Kacho M.A., Niaki H.A., Tarighati M., Alaee E. The Association between Prolonged Jaundice and TATA Box Dinucleotide Repeats in Gilbert's Syndrome. J Clin Diagn Res. 2017; 11(9): GC05-GC07. DOI: https://doi.org/10.7860/jcdr/2017/19376.10597
24. Radoi V.E., Ursu R.I., Poenaru E., Arsene C., Bohiltea C.L., Bohiltea R. Frequency of the UGT1A1*28 polymorphism in a Romanian cohort of Gilbert syndrome individuals. J Gastrointestin Liver Dis. 2017 Mar; 26(1): 25-8. DOI: https://doi.org/10.15403/jgld.2014.1121.261.ugt URL: https://pubmed.ncbi.nlm.nih.gov/28338110/
25. Rasool A., Sabir S., Ashlaq M., Farooq U., Khan M.Z., Khan F.Y. Gilbert's syndrome – a concealed adversity for physicians and surgeons. J Ayub Med Coll. 2015; 27(3): 707-10. https://www.sid.ir/en/journal/ViewPaper.aspx?ID=561260
26. Rauchschwalbe S.K., Zühlsdorf M.T., Wensing G., Kuhlmann J. Glucuronidation of acetaminophen is independent of UGT1A1 promotor genotype. Int J Clin Pharmacol Ther. 2004 Feb; 42(2): 73-7. DOI: https://doi.org/10.5414/cpp42073
27. Simondsen K.A., Kolesar J.M. Lenalidomide-induced elevated bilirubin. J Oncol Pharm Pract. 2012; 18(4): 402-5. DOI: https://doi.org/10.1177%2F1078155212439492
28. Singh A., Jialal I. Unconjugated hyperbilirubinemia. StatPearls [Internet]. 2020. https://www.ncbi.nlm.nih.gov/books/NBK562172/
29. Spraggs C.F., Parham L.R., Hunt C.M., Dollery C.T. Lapatinib-induced liver injury characterized by class II HLA and Gilbert's syndrome genotypes. Clin Pharmacol Ther. 2012; 91(4): 647-52. DOI: https://doi.org/10.1038/clpt.2011.277
30. Strassburg C.P. Gilbert-Meulengracht's syndrome and pharmacogenetics: is jaundice just the tip of the iceberg? Drug Metab Rev. 2010; 42(1): 168-81. DOI: https://doi.org/10.3109/03602530903209429
31. Strassburg C.P. Pharmacogenetics of Gilbert's syndrome. Pharmacogenomics. 2008; 9(6): 703-15. DOI: https://doi.org/10.2217/14622416.9.6.703
32. Tolomeo M., Colomba C., Meli M., Cascio A. Hepatotoxicity caused by mebendazole in a patient with Gilbert's syndrome. J Clin Pharm Ther. 2019; 44(6): 985-7. DOI: https://doi.org/10.1111/jcpt.13033
33. Vitek L., Bellarosa C., Tiribelli C. Induction of Mild Hyperbilirubinemia: Hype or Real Therapeutic Opportunity? Clin Pharmacol Ther. 2019; 106(3): 568-75. DOI: https://doi.org/10.1002/cpt.1341
34. Wagner K-H., Shiels R.G., Lang C.A., Khoei N.S. Bulmer A.C. Diagnostic criteria and contributors to Gilbert's syndrome. Crit Rev Clin Lab Sci. 2018; 55(2): 129-39. DOI: https://doi.org/10.1080/10408363.2018.1428526

Conflicts of interest: authors have no conflict of interest to declare.
Received: 02.12.2020
Revised: 20.12.2020
Accepted: 22.12.2020

СИНДРОМ ЖИЛЬБЕРА: КЛІНІКО-ФАРМАКОЛОГІЧНІ АСПЕКТИ. Огляд

Хайтович М.В., Турчак Д.В.

Національний медичний університет імені О.О. Богомольця, Київ, Україна
nik3061@gmail.com

Актуальність. На даний момент продовжуться активне вивчення особливостей метаболізму лікарських засобів у пацієнтів із синдромом Жильбера, оскільки з ним може бути пов'язаний як ризик виникнення дозозалежних побічних реакцій, так і неефективності лікування.

Мета: узагальнити відомості різних авторів щодо особливостей застосування лікарських засобів у пацієнтів із синдромом Жильбера.

Методи. Аналіз наукових публікацій в міжнародній електронній наукометричній базі даних PubMed за ключовими словами. Глибина пошуку – 10 років (2010-2019 рр.).

Результати. Синдром Жильбера відмічається у 3-10% населення і характеризується ізольованим підвищенням рівня білірубіну в крові до помірних значень без змін інших біохімічних показників функції печінки та без пошкодження її структури. Синдром Жильбера успадковується аутосомно-рецесивно і переважно обумовлений наявністю додаткового динуклеотида тимін-аденін (ТА) на промоторній ділянці A(TA)6TAA гена, що кодує фермент UGT1A1. Подовження промоторної послідовності призводить до зменшення утворення UGT1A1. При варіанті A(TA)7TAA рівень продукції ферменту може бути знижений до 80% від норми у гетеро- і до 20% у гомозигот, відповідно. Синдром Жильбера проявляється підвищенням рівня непрямого білірубіну крові, жовтяницею шкіри і слизових оболонок, болями в животі, а також диспепсією і астеновегетативним синдромом. Інтермітуюча іктеричність склер і шкіри виникає на тлі дії екзо- і ендогенних факторів, таких як голодування, зневоднення, інфекційні захворювання, емоційне і фізичне напруження, гемоліз або менструація, вживання алкоголю, гормональна контрацепція тощо, зазвичай при концентрації білірубіну, що перевищує 40-45 мкмоль/л. Серед ускладнень гіпербілірубінемії при синдромі Жильбера – розвиток жовчокам'яної хвороби, в тому числі – у дітей та підлітків. Синдром Жильбера асоціюється із порушенням метаболізму деяких лікарських засобів – аглюконів. До них відносяться анаболічні стероїди, глюкокортикоїди, андрогени, рифампіцин, циметидин, хлорамфенікол, стрептоміцин, саліцилат натрію, ампіцилін, кофеїн, етиніл-естрадіол, парацетамол, ібупрофен, кетопрофен, сульфаніламіди, діакарб, ментол, кофеїн, статини та ін. Клінічною особливістю синдрому Жильбера є поява або посилення жовтяниці, пов'язаної з прийомом таких лікарських засобів. В умовах дефіциту UGT1 лікарські засоби конкурують з білірубіном за фермент, що веде до підвищення рівня непрямого білірубіну в сироватці крові. Тому для профілактики ураження печінки необхідно в кожному конкретному випадку оцінювати ризик та користь медикаментозного лікування пацієнтів із синдромом Жильбера.

Висновок. Синдром Жильбера відноситься до поширених патологічних станів і тому важливо як можна раніше його діагностувати. Враховуючи, що застосування препаратів-аглюконів у пацієнтів із синдромом Жильбера може бути причиною розвитку медикаментозного ураження печінки, необхідно в кожному конкретному випадку оцінювати ризик та користь медикаментозного лікування пацієнтів із синдромом Жильбера.

Ключові слова: синдром Жильбера, лікарські засоби, метаболізм, фармакогенетика

СИНДРОМ ЖИЛЬБЕРА: КЛИНИКО-ФАРМАКОЛОГИЧЕСКИЕ АСПЕКТЫ. Обзор

Хайтович Н.В., Турчак Д.В.

Национальный медицинский университет имени А.А. Богомольца, Киев, Украина

nik3061@gmail.com

Актуальность. На данный момент продолжается активное изучение особенностей метаболизма лекарственных средств у пациентов с синдромом Жильбера, поскольку с ним может быть связан как риск возникновения дозозависимых побочных реакций, так и неэффективности лечения.

Цель: обобщить сведения разных авторов относительно особенностей применения лекарственных средств у пациентов с синдромом Жильбера.

Методы. Анализ научных публикаций в международной электронной наукометрической базе данных PubMed по ключевым словам. Глубина поиска – 10 лет (2010-2019 гг.).

Результаты. Синдром Жильбера отмечается у 3-10% населения и характеризуется изолированным повышением уровня билирубина в крови до умеренных значений без изменений других биохимических показателей функции печени и без повреждения ее структуры. Синдром Жильбера наследуется аутосомно-рецессивно и преимущественно обусловлен наличием дополнительного динуклеотида тимина-аденина (ТА) на промоторной области A(TA)6TAA гена, кодирующего фермент UGT1A1. Продление промоторной последовательности приводит к уменьшению образования UGT1A1. При варианте A(TA)7TAA уровень продукции фермента может быть снижен до 80% от нормы у гетеро- и до 20% у гомозигот, соответственно. Синдром Жильбера проявляется повышением уровня непрямого билирубина крови, желтухой кожи и слизистых оболочек, болями в животе, а также диспепсией и астеновегетативным синдромом. Интермиттирующая иктеричность склер и кожи возникает на фоне действия экзо- и эндогенных факторов, таких как голодание, обезвоживание, инфекционные заболевания, эмоциональное и физическое напряжение, гемолиз, менструация, употребление алкоголя, гормональная контрацепция и т.п., обычно при концентрации билирубина, превышающей 40-45 мкмоль/л. Среди осложнений гипербилирубинемии при синдроме Жильбера – развитие желчекаменной болезни, в том числе – у детей и подростков. Синдром Жильбера ассоциируется с нарушением метаболизма некоторых лекарственных средств – аглюконов. К ним относятся анаболические стероиды, глюкокортикоиды, андрогены, рифампицин, циметидин, хлорамфеникол, стрептомицин, салицилат натрия, ампициллин, кофеин, этинил-эстрадиол, парацетамол, ибупрофен, кетопрофен, сульфаниламиды, диакарб, ментол, кофеин, статины и др. Клинической особенностью синдрома Жильбера является появление или усиление желтухи, связанной с приемом таких лекарственных средств. В условиях дефицита UGT1 лекарственные средства конкурируют с билирубином за фермент, это ведет к повышению уровня непрямого билирубина в сыворотке крови. Поэтому для профилактики поражения печени необходимо в каждом конкретном случае оценивать риск и пользу медикаментозного лечения пациентов с синдромом Жильбера.

Выводы. Синдром Жильбера относится к распространенным патологическим состояниям и поэтому важно как можно раньше его диагностировать. Учитывая, что применение препаратов-аглюконов у пациентов с синдромом Жильбера может быть причиной развития медикаментозного поражения печени, необходимо в каждом конкретном случае оценивать риск и пользу медикаментозного лечения пациентов с синдромом Жильбера.

Ключевые слова: синдром Жильбера, лекарственные средства, метаболизм, фармакогенетика